

# A 5-Year Prospective Study of Implant-Supported Single-Tooth Replacements

(Une étude prospective sur une période de 5 ans  
des prothèses constituées d'une seule dent fixées par implant)

- Leslie Laing Gibbard, BSc, BEd, MSc, PhD, DDS •
- George Zarb, BChD, DDS, MS, MS, FRCD(C) •

## S o m m a i r e

**Objectif :** Étant donné que l'ostéo-intégration a été un succès dans le traitement de patients complètement édentés, il est tentant d'extrapoler ces résultats et d'en déduire qu'ils réussiront pour une prothèse constituée d'une seule dent. Toutefois, il existe des différences cliniques majeures entre les patients complètement édentés et les patients partiellement édentés. Cette étude prospective est le suivi d'une étude commencée à l'Université de Toronto en 1986. L'objectif de cette étude était de poursuivre une évaluation longitudinale de prothèses constituées d'une seule dent fixées par implant.

**Méthodes :** La première étude portait sur 42 patients traités consécutivement avec un total de 49 implants. Le groupe de patients se composait entièrement de patients de l'Université de Toronto, traités avec des implants Brånemark, dont le traitement avait été terminé plus de 5 ans auparavant (c.-à-d. avant 1994). Aucun critère d'exclusion ne s'appliquait. Un implant n'était pas ostéo-intégré au moment de l'étape 2 de la chirurgie et 6 patients avec des implants ostéo-intégrés dits réussis n'étaient pas disponibles au moment du rappel. Pour préparer ce rapport, 30 des 42 implants restants ont été évalués dans le cadre d'examens de rappel. L'évaluation de la réussite des implants était basée sur les critères publiés. De plus, l'apparence du tissu conjonctif, l'immobilité de l'implant, les contacts occlusaux dans les excursions centrées, les contacts proximaux, l'étanchéité de la couronne et des vis pilier et les réponses des patients aux questionnaires de satisfaction ont été évalués.

**Résultats :** Les 30 prothèses constituées d'une seule dent fixées par implant, en place depuis 5 ans ou plus, ont satisfait aux critères servant à déterminer le succès du traitement par prothèse sur implant. Chaque implant était immobile et avait une perte osseuse verticale de moins de 0,2 mm chaque année.

**Conclusion :** Il est possible d'obtenir des résultats à long terme stables avec les couronnes sur implant constituées d'une seule dent Brånemark.

**Mots clés MeSH :** dental implants; dental prosthesis, implant-supported; osseointegration

© J Can Dent Assoc 2002; 68(2):110-6  
Cet article a fait l'objet d'une révision par des pairs.

The success of osseointegration<sup>1,2</sup> in the management of completely edentulous patients is well documented in both in vitro and in vivo studies.<sup>3-9</sup> Although it is tempting to extrapolate from these results to infer success of single-tooth replacement, there are major clinical differences between edentulous and partially edentulous patients, such as the presence of adjacent teeth; the more challenging esthetic demands, particularly in the anterior regions; and differences in occlusal forces and prosthetic designs. However, with broadening patient awareness of treatment alternatives,

implant-supported crowns are being used increasingly in cases of single-tooth loss.

Preliminary outcomes of treatment with Brånemark single-tooth implant-supported prostheses inserted at the University of Toronto were reported in 1996.<sup>10</sup> Those results, as well as results from a similar study,<sup>11</sup> indicated promising performance in different jaw locations. At the time, there were no long-term studies offering specific criteria for optimal functional and esthetic results with minimal risk of morbidity.

**Table 1** Number of implants per patient

No. of implants per patient	No. (and %) of patients	
1	24	(80)
2	5	(17)
3	1	(3)
Total	30	(100)

The purpose of this study was to continue the longitudinal assessment of the same implant-supported single-tooth replacements, after service for 5 or more years. Outcomes were assessed clinically, radiographically and esthetically, the latter from the patients' perspective as well as the viewpoint of various dental personnel, including dental assistants, dental students and dentists.

## Materials and Methods

### Study Population

The original study was initiated in 1986 at the Implant Prosthodontic Unit (IPU) at the University of Toronto, Toronto, Ontario. The study population consisted of 42 consecutively treated patients with a total of 49 Brånemark single-tooth implants.<sup>10</sup> Of the 42 patients, 17 (40%) were female and 25 (60%) were male; the patients ranged in age from 14.5 to 63.9 years (mean 33.5 years) at the time of implant placement. Thirty-six patients (86%) were treated with a single implant at one site, 5 patients (12%) received a single implant at each of 2 sites, and one patient (2%) received a single implant at each of 3 sites. The teeth being replaced had been missing for at least 1 year. The patient group for the current study, which started in 1999, consisted of all patients who had received a single tooth implant at the University of

Toronto whose treatment had been completed over 5 years ago (before 1994). No exclusion criteria applied.

Thirty of the original 49 implants were assessed in the current study: 14 (47%) in women and 16 (53%) in men. The 24 patients ranged in age from 23 to 74 years (mean 42.7, median 40.5, standard deviation 13.9). The number of single-tooth implants per patient is listed in **Table 1**, the mean number of implants per subject being  $1.2 \pm 0.5$ . Nineteen implants (63%) had been placed in zone 1 (anterior to the mental foramen), 18 (60% of the total) in the maxilla and 1 (3%) in the mandible. Eleven implants (37%) had been placed in zone 2 (posterior to the mental foramen), 3 (10% of the total) in the maxilla and 8 (27%) in the mandible.

### Clinical, Esthetic Radiographic Assessments

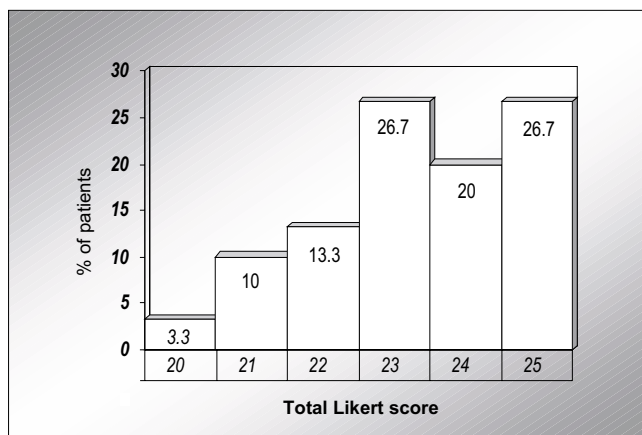
Each patient received a consent form, which included a written explanation of the nature of the assessment to be undertaken. One of the authors (L.L.G.) performed all of the clinical examinations. Soft-tissue appearance, implant mobility, occlusal contacts in centric occlusion and excursions, proximal contacts, tightness of crown and abutment screws, and patients' responses on a satisfaction questionnaire (**Table 2**) were evaluated.

In all but 2 cases, in which the crowns had been cemented, the crowns were removed, ultrasonically cleaned and re-inserted. Five standardized photographs were taken: full face, natural smile, full smile, cheek-retracted smile and occlusal view using a mirror. For this part of the study, dental assistants, dental students and dentists were asked to complete esthetic evaluation forms on the basis of the cheek-retracted smile and occlusal-view photographs.

Standardized intraoral periapical radiographs were obtained to assess for radiolucencies and changes in crestal

**Table 2** Assessment of patient satisfaction

	Patient response; no. (and %) of patients				
	Extremely dissatisfied or unwilling	Somewhat dissatisfied or unwilling	Neither satisfied/willing nor dissatisfied/unwilling	Somewhat satisfied or willing	Extremely satisfied or willing
To what degree are you generally satisfied with the appearance of your implant-supported crown?				3 (10)	27 (90)
To what degree are you generally satisfied with the functioning of your implant-supported crown?				5 (17)	25 (83)
To what extent are you generally satisfied with the cleansability of your implant-supported crown?		2 (7)	1 (3)	9 (30)	18 (60)
To what extent would you be willing to undergo another implant-supported crown procedure?		2 (7)	4 (13)	8 (27)	16 (53)
To what extent would you be willing to recommend the implant-supported crown procedure to a relative or close friend?				4 (13)	26 (87)



**Figure 1:** Distribution of total Likert scores for satisfaction among 24 patients. Total patient satisfaction scores, as determined by the 5-level Likert scale, had a potential range of 5 to 25. The mean score was 23.3 (standard deviation 1.44).

bone level. To standardize the radiographs, a radiographic film holder was inserted into the implant and held in place by means of a guide pin while the radiograph was being taken. Each radiograph was then digitized. Measurements of bone reduction were determined by standardizing the distance between implant threads at 3 mm and by measuring crestal bone levels at the mesial and distal sides of each implant and at the adjacent surfaces of neighbouring teeth.

### Statistical Analysis

Univariate analyses were used to describe the number of subjects, the number of implants, the number of implants per subject, the age of the subjects, the zone in which the implants had been placed, and the sex distribution. Univariate analyses were also used in the descriptions of fixture and abutment lengths; retrievability of the crown; parafunctional habits of the patient (grinding or clenching); history of occlusal splints and whether such splints were worn by the patient; contact in excursions; abutment reflections beneath the soft tissue; soft-tissue deficiencies; evidence of inflammation, fistulae, dehiscence or mobility; interproximal contact with adjacent teeth; tightness of the crown and abutment screws; and patient satisfaction as determined with a 5-level Likert scale. In addition, univariate analysis was used to describe annual mean bone reduction after a minimum of 5 years of loading on the mesial and distal sides of each implant and at adjacent surfaces of neighbouring teeth as well as overall annual bone reduction around the implant.

Bivariate analyses were carried out between the patient satisfaction scores and the various implant data. Chi-square and Fisher's exact tests were performed, with the null hypothesis that there was no association between patient dissatisfaction (dichotomous variable) and various implant parameters. Pearson's correlation coefficient was used to determine whether annual bone reduction on the mesial or distal side of the implant was significantly associated with annual bone reduction on the distal or mesial side of the adjacent tooth, respectively.

**Table 3** Short-term and long-term clinical success of 49 implants

Outcome	Definition	No. of implants	
		Short-term <sup>a</sup>	Long-term <sup>b</sup>
Success	Implant met success criteria <sup>1, 2</sup>	42	30
Survival	Implant not checked clinically or radiographically at last recall	6	12
Unaccounted	Patient died, dropped out or was not available at recall	0	6
Failure	Implant removed for any reason	1	1

<sup>a</sup>As of last recall visit in 1994.<sup>10</sup>

<sup>b</sup>Follow-up after at least 5 years (in 1999).

Multivariate analyses were performed with logistic regression models for predicting patient dissatisfaction as determined by the clinical, radiographic and esthetic measures on a forward stepwise basis.

## Results

### Treatment Outcome

Of the 42 patients with 49 implants in the original study,<sup>10</sup> all but one, whose implant had not osseointegrated at stage 2 surgery, had been seen for regular recall visits for a minimum of 4 years after crown insertion. Six (14%) of the 42 patients, accounting for 6 (12%) of the 48 reportedly successful osseointegrated implants (5 in the maxilla and 1 in the mandible), had moved by the time of the current study and were unavailable for recall. Each had last been seen for their 4-year recall appointment in 1994. Twelve of the implants were not checked clinically or radiographically; 8 of the patients, accounting for 8 of these implants, were contacted by telephone. All reported both functional and esthetic satisfaction with their implant-supported crowns, which suggested that the implants had survived. All 30 of the examined implants met the published success criteria.<sup>1,2</sup> Short-term clinical success (as of 1996) and the results of a minimum 5-year (maximum 13-year) loading period for the 49 implants are shown in **Table 3**.

Twenty (67%) of the fixtures were 13 mm in length, 5 (17%) were 10 mm, 4 (13%) were 15 mm, and 1 (3%) was 18 mm. Almost half of the abutments (14 [47%]) were 4.0 mm long, whereas the others were either 3.0 mm (7 [23%]) or 5.5 mm (9 [30%]). All but 2 of the crowns were retrievable through access openings in the restorations. Most were retained with slotted screws.

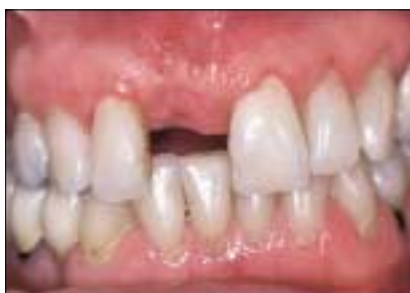Nine (38%) of the 24 patients were aware of grinding their teeth, whereas 10 (42%) claimed that they clenched their teeth. Six patients (25%) had previously been prescribed an occlusal splint, but only 2 (8%) still used one.

**Table 4 Annual bone reduction<sup>a</sup> associated with 30 successful implants**

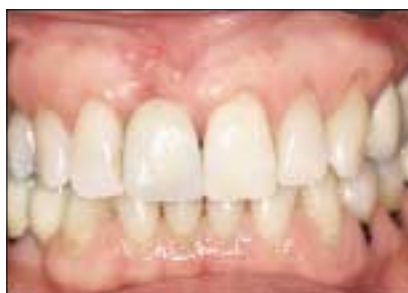Location	No. of implants	Mean	Annual bone reduction (mm)			
			Median	Standard deviation	Minimum	Maximum
Mesial side of implant	30	0.069	0.069	0.037	-0.028	0.140
Distal side of implant	30	0.070	0.070	0.058	-0.114	0.262
Distal side of adjacent tooth	14	0.302	0.217	0.280	0.007	1.060
Mesial side of adjacent tooth	15	0.277	0.228	0.289	0.005	1.138
Overall annual bone reduction <sup>b</sup>	30	0.073	0.071	0.044	-0.064	0.199

<sup>a</sup>Negative values indicate bone gain.

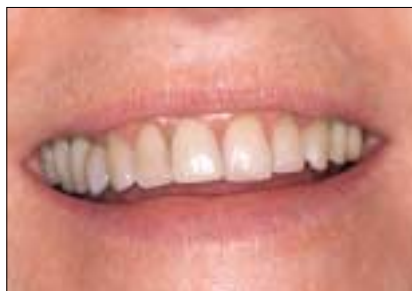<sup>b</sup>Overall annual bone reduction is the mean of annual bone reduction at the mesial and distal sides of the same implant.



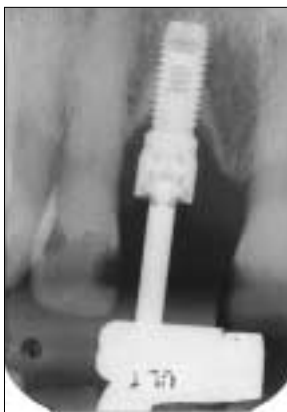**Fig. 2a:** Pre-operative photograph of edentulous site 11 in a 67-year-old woman.



**Fig. 2b:** Post-operative photograph of the restored single-tooth implant at site 11.



**Fig. 2c:** Photograph of the full smile of the patient showing the completed result of restored implant at site 11.



**Fig. 2d:** Periapical radiograph of the implant at site 11.

Four (13%) of the 30 implants had contact in centric occlusion. Seven (23%) of the implants had contact in lateral and protrusive excursions. Abutment reflection (seen as a grey shadow) under the soft tissue was noted with 7 (23%) of the implants, whereas 8 (27%) had a soft-tissue deficiency. Gingival tissue around 3 (10%) of the implants showed signs of inflammation. None of the implants was associated with fistulae, dehiscence or mobility. Twenty-three implants (77%) had mesial interproximal contact with the adjacent tooth, and 25 (83%) exhibited distal contact. Loose gold screws were found in 4 (13%) of the crowns, but all had gone unnoticed by the patients. No looseabutment screws were observed.

Figures 2 to 4 are typical pre- and post-operative photographic and radiographic images of single-tooth implants in the anterior zone.

### **Self-Reported Satisfaction with Implant-Supported Prostheses**

The distribution of responses from the 24 patients to questions about their satisfaction with and the esthetic characteristics of their implants are presented in Fig. 1 and Table 2. Total patient satisfaction scores, as determined by a 5-level Likert scale, had a potential range of 5 to 25. None of the implants received a total score less than 20. At least 80% of the responses were in the somewhat satisfied (or willing) or extremely satisfied (or willing) categories (see Table 2).

### **Radiographic Findings**

All implants were free of radiographic signs of morbidity. Mean annual bone reduction was 0.069 mm at mesial sites, 0.070 mm at distal sites and 0.073 mm overall (Table 4). In situations where the implant-supported crowns had contact in centric occlusion or lateral and protrusive excursions, the mean annual bone reduction

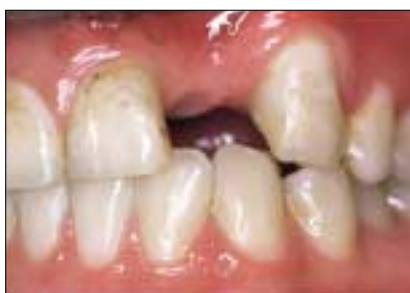at the mesial side of both the implant and the adjacent tooth was higher than in situations where there were no such contacts. However, the levels of bone reduction were within the defined range as successful according to the published criteria.<sup>1,2</sup> Correlations between annual bone reduction on the mesial or distal side of the implant and annual bone reduction on the distal or mesial side, respectively, of the adjacent tooth were not significant (Table 5).

### **Esthetic Evaluation by Dental Personnel**

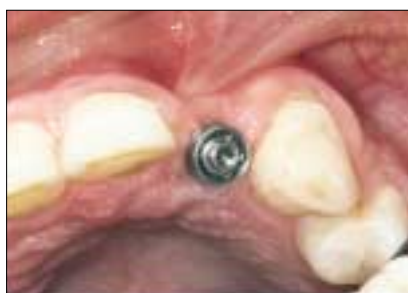Preliminary results of the esthetic evaluation by dental personnel revealed that all but 3 of the crowns had ideal esthetic appearance. Two of these crowns had satisfactory or

**Table 5 Correlations between annual bone reduction on mesial or distal side of the implant with reduction on distal or mesial side, respectively, of the adjacent tooth**

	Annual bone reduction on distal side of adjacent tooth	Annual bone reduction on mesial side of adjacent tooth
<b>Annual bone reduction on mesial side of implant</b>		
Pearson correlation	0.19	
p value (2-tailed)	0.52	
No. of implants	14	
<b>Annual bone reduction on distal side of implant</b>		
Pearson correlation		0.34
p value (2-tailed)		0.21
No. of implants		15



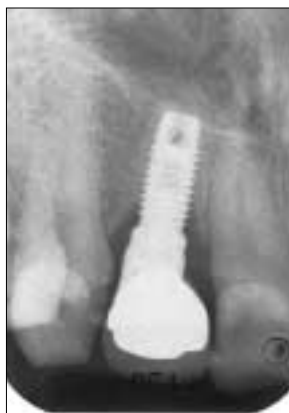**Fig. 3a:** Pre-operative photograph of edentulous site 22 in a 37-year-old man.



**Fig. 3b:** Post-operative photograph of the restored single-tooth implant at site 22.



**Fig. 3c:** Photograph of the full smile showing the completed result of restored implant at site 22.



**Fig. 3d:** Periapical radiograph of the implant at site 22.

tion in the prevention of occlusal overload on implants is that of tactile sensitivity, which is reportedly 3 times less on implants than on teeth.<sup>12</sup> Although 7 implants had occlusal contacts in centric occlusion or excursions, only one patient with such contacts reported the use of an occlusal splint at night. The loading limits of a single implant in different host sites in the jawbones are not known. Long-term success for multiple splinted implants cannot be extrapolated to single implants. Hence the dentist must be particularly prudent in planning single-tooth implants in the context of anticipated differences in magnitude, frequency and duration of forces acting on the replaced single crown. The premise of treatment planning in the IPU has been to “protect” the single implant as much as possible by minimizing or even precluding occlusal contacts on the crown in both centric contact and excursive positions. In fact, the single implant is regarded more as an elegant and ecologically sound space maintainer than as a crown replacement. The comparison of full loading, partial loading and no loading for single implants at different jaw sites and over longer periods of observations clearly deserves investigation.

reasonably good characteristics, and the characteristics of the third were considered poor. Further results from this portion of the study will be submitted for publication at a later date.

### Discussion

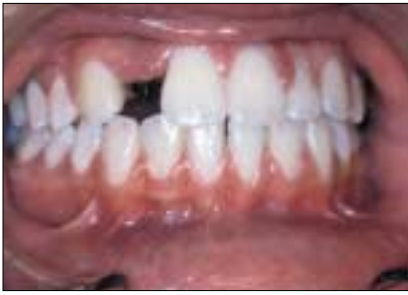The present study indicates that predictable, long-term results can be achieved with single Brånemark implant-supported crowns.

The 30 implants examined had a mean vertical bone reduction of less than 0.2 mm per year, but the mean annual bone reduction was greater for implant-supported crowns with contacts in centric occlusion or excursions than for those for which there were no such contacts. An important considera-

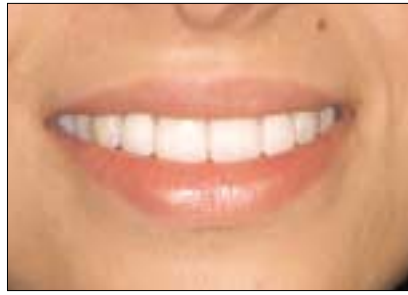Annual marginal bone reduction around implants was less than 0.2 mm per year after the first year of loading, which corresponds with other published results.<sup>1,2</sup> Mean annual bone reduction at mesial sites, at distal sites and overall (Table 4) was consistent with findings in other studies of single-tooth implants.<sup>13-18</sup> Previous reports<sup>11,15</sup> have confirmed that the presence of a single-tooth implant promotes crestal bone reduction at the implant-facing surfaces of adjacent teeth.

Patient satisfaction with single-implant crowns was very high in this patient group and in other studies.<sup>10,11,14,17,19</sup> Dissatisfaction with the implants did not appear to be correlated with any complications that may have arisen during the loading period, such as loosening of crown or abutment screws or

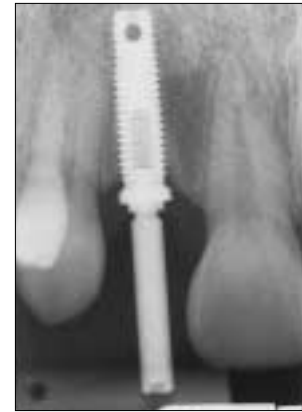



**Fig. 4a:** Pre-operative photograph of edentulous site 12 in a 25-year-old woman.



**Fig. 4b:** Post-operative photograph of the restored single-tooth implant at site 12.



**Fig. 4c:** Periapical radiograph of the implant at site 12.

inflammation, although one patient reported dissatisfaction because of abutment reflection under the gingiva.<sup>17</sup> Fistulae have been reported in association with loose abutment screws.<sup>10,13</sup> However, neither fistulae formation nor loose abutment screws were observed in the current study.

At present, only preliminary data are available from the esthetic evaluation. However, indications are that the results will be similar to those previously reported,<sup>20-23</sup> specifically, that patients and dentists have different criteria when judging esthetics and quality of dental care. Chang and others<sup>23</sup> found that no single factor used in multiple regression analysis influenced patients' satisfaction with the appearance of the crown at a statistically significant level. It appears that a patient's concept of esthetic appearance differs substantially from that of the dentist. Although both may have the same preferences for the shape of maxillary anterior teeth, for example, preferences for proportions of length and width appear to differ. Factors considered by professionals to be of significance for the esthetic result of restorative treatment may not be of decisive importance for patients. Of the data collected to date, dental students' opinions were between those of the patients and those of the dentists.

This study will be continued with expansion of the patient base, as a larger sample will afford more reliability. The analysis of esthetics will also continue.

## Conclusion

In this study, the criteria for success of implant prosthodontics were met by all 30 of the single-tooth implants examined, which had been in place for 5 or more years. Each implant was immobile, and each had a mean vertical bone reduction of less than 0.2 mm annually. All but 3 of the implant-supported crowns met with patient and dentist satisfaction, exhibiting lack of pain, discomfort, altered sensation and infection. It appears that single-implant therapy to support a crown is a viable prosthodontic treatment option, at least in the short term. ➤

*Remerciements : Les auteurs aimeraient remercier Snezana Djuric, Janet deWinter et le personnel de l'Unité de dentisterie prothétique pour leur aide clinique, toujours offerte avec bonne humeur. Cette étude a reçu une subvention de soutien de Nobel Biocare inc. et de la faculté de médecine dentaire de l'Université de Toronto.*

*La Dre Laing Gibbard est dentiste résidente en prosthodontie, faculté de médecine dentaire, Université de Toronto, Toronto (Ontario).*

*Le Dr Zarb est professeur et directeur, prosthodontie, au département des sciences cliniques, faculté de médecine dentaire, Université de Toronto.*

*Écrire au : Dre Leslie Laing Gibbard, Faculté de médecine dentaire, Université de Toronto, 124, rue Edward, Toronto (Ontario) M5G 1G6. Courriel : leslie.lainggibbard@utoronto.ca.*

*Les auteurs n'ont pas d'intérêt financier déclaré dans la ou les sociétés qui fabriquent les produits mentionnés dans cet article.*

## Références

- Albrektsson T, Zarb GA. Current interpretations of the osseointegrated response: clinical significance. *Int J Prosthodont* 1993; 6(2):95-105.
- Zarb GA, Albrektsson T. Consensus report: towards optimized treatment outcomes for dental implants. *Int J Prosthodont* 1998; 11(5):389.
- Brånemark P-I, Hansson BO, Adell R, Breine U, Lindström J, Hallen O, and other. Osseointegrated implants in the treatment of the edentulous jaw. Experience from a 10-year period. *Scand J Plast Reconstr Surg* 1977; 11(suppl 16):1-132.
- Lindquist LW, Carlsson GE. Long-term effects on chewing with mandibular fixed prostheses on osseointegrated implants. *Acta Odontol Scand* 1985; 43(1):39-45.
- van Steenberghe D, Quirynen M, Calberson L, Demanet M. A prospective evaluation of the fate of 697 consecutive intraoral fixtures ad modum Brånemark in the rehabilitation of edentulism. *J Head Neck Pathol* 1987; 6:53-58.
- Albrektsson T. A multicenter report on osseointegrated oral implants. *J Prosthet Dent* 1988; 60(1):75-84.
- Adell R, Eriksson B, Lekholm U, Brånemark PI, Jemt T. Long-term follow-up study of osseointegrated implants in the treatment of totally edentulous jaws. *Int J Oral Maxillofac Implants* 1990; 5(4):347-59.
- Zarb GA, Schmitt A. Osseointegration and the edentulous predicament. The 10-year-old Toronto study. *Br Dent J* 1991; 170(12):439-44.
- Harle TJ, Anderson JD. Patient satisfaction with implant-supported prostheses. *Int J Prosthodont* 1993; 6(2):153-62.
- Avivi-Arber L, Zarb GA. Clinical effectiveness of implant-supported single-tooth replacement: the Toronto study. *Int J Oral Maxillofac Implants* 1996; 11(3):311-21.
- Henry PJ, Laney WR, Jemt T, Harris D, Krogh PH, Polizzi G, and others. Osseointegrated implants for single-tooth replacement: a prospective 5-year multicenter study. *Int J Oral Maxillofac Implants* 1996; 11(4):450-5.
- Jacobs R, van Steenberghe D. Comparative evaluation of the oral tactile function by means of teeth or implant-supported prostheses. *Clin Oral Implants Res* 1991; 2(2):75-80.

13. Laney WR, Jemt T, Harris D, Henry PJ, Krogh PH, Polizzi G, and others. Osseointegrated implants for single-tooth replacement: progress report from a multicenter prospective study after 3 years. *Int J Oral Maxillofac Implants* 1994; 9(1):49-54.
14. Andersson B, Ödman P, Lindvall AM, Brånemark PI. Five-year prospective study of prosthodontic and surgical single-tooth implant treatment in general practices and at a specialist clinic. *Int J Prosthodont* 1998; 11(4):351-5.
15. Esposito M, Ekestubbe A, Grondahl K. Radiological evaluation of marginal bone loss at tooth surfaces facing single Brånemark implants. *Clin Oral Implants Res* 1993; 4(3):151-7.
16. Scheller H, Urgell JP, Kultje C, Klineberg I, Goldberg PV, Stevenson-Moore P, and others. A 5-year multicenter study on implant-supported single crown restorations. *Int J Oral Maxillofac Implants* 1998; 13(2):212-8.
17. Scholander S. A retrospective evaluation of 259 single-tooth replacements by the use of Brånemark implants. *Int J Prosthodont* 1999; 12(6):483-91.
18. Johnson RH, Persson GR. Evaluation of a single-tooth implant. *Int J Oral Maxillofac Implants* 2000; 15(3):396-404.
19. Levine RA, Clem DS 3rd, Wilson TG Jr, Higginbottom F, Saunders SL. A multicenter retrospective analysis of the ITI implant system used for single-tooth replacements: preliminary results at 6 or more months of loading. *Int J Oral Maxillofac Implants* 1997; 12(2):237-42.
20. Brisman AS. Esthetics: a comparison of dentists' and patients' concepts. *J Am Dent Assoc* 1980; 100(3):345-52.
21. Abrams RA, Ayers CS, Vogt Petterson M. Quality assessment of dental restorations: a comparison by dentists and patients. *Community Dent Oral Epidemiol* 1986; 14(6):317-9.
22. Rimmer SE, Mellor AC. Patients' perceptions of esthetics and technical quality in crowns and fixed partial dentures. *Quintessence Int* 1996; 27(3):155-62.
23. Chang M, Ödman PA, Wennström JL, Andersson B. Esthetic outcome of implant-supported single-tooth replacements assessed by the patient and by prosthodontists. *Int J Prosthodont* 1999; 12(4):335-41.

---

LE CENTRE DE  
DOCUMENTATION  
DE L'ADC

---

Le Centre de documentation a préparé un dossier de documentation sur **les implants unitaires**. Les membres de l'ADC peuvent se le procurer pour la somme de 10 \$, taxes applicables en sus. Communiquez avec le Centre de documentation, tél. : **1-800-267-6354** ou **(613) 523-1770**, poste 2223; téléc. : **(613) 523-6574**; courriel : **info@cda-adc.ca**.

---