

# Orthodontic Extrusion: Periodontal Considerations and Applications

• Normand Bach, DMD •

• Jean-François Baylard, BSc, DMD, Dip Perio •

• René Voyer, BSc, DMD, MSc, Dip Perio, FRCD(C), Diplomate of the American Board of Periodontology •

## A b s t r a c t

*Human teeth erupt naturally to compensate for tooth wear and tear. When a subgingival lesion such as crown fracture occurs, the general practitioner must consider orthodontic extrusion of the tooth to allow for prosthetic rehabilitation. However, because this therapeutic approach is not appropriate in all cases, each tooth must be carefully analyzed before treatment. The amount of force applied depends on the desired effect. Orthodontic extrusion can also be used to augment bone and tissue in the course of preparing an implant site. In most cases, endodontic treatment must be completed first, with close attention being paid to the contour of the final restoration. The benefits of extrusion are clear, but patients must nonetheless be informed of the disadvantages.*

**MeSH Key Words:** crown lengthening; tooth fractures/therapy; tooth movement/methods

© J Can Dent Assoc 2004; 70(11):775-80  
This article has been peer reviewed.

In everyday practice, the general practitioner sometimes sees cases of subgingival trauma or carious lesions. Possible therapeutic options include extraction and prosthetic restoration (by a bridge) or surgical lengthening of the crown, as well as orthodontic extrusion. The last of these options provides undeniable benefits for the patient.

### Orthodontic Extrusion

Movement of a tooth by extrusion involves applying traction forces in all regions of the periodontal ligament to stimulate marginal apposition of crestal bone. Because the gingival tissue is attached to the root by connective tissue, the gingiva follows the vertical movement of the root during the extrusion process. Similarly, the alveolus is attached to the root by the periodontal ligament and is in turn pulled along by the movement of the root.

### Rapid Extrusion

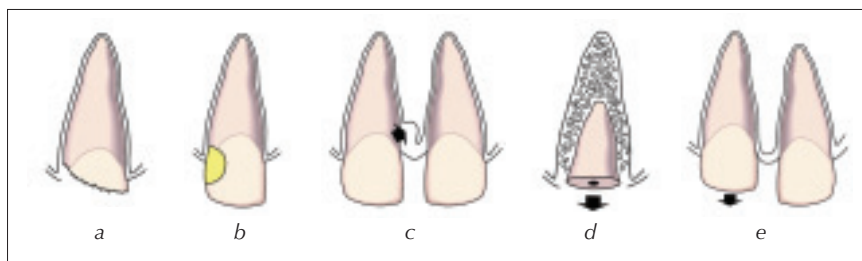
In the normal course of events, bone and gingival movements are produced under low-intensity extrusive forces. When stronger traction forces are exerted, as in rapid extrusion, coronal migration of the tissues supporting the tooth is less pronounced because the rapid movement exceeds their capacity for physiologic adaptation.<sup>1</sup> As well, rapid

extrusion must be followed by an extended retention period<sup>2</sup> to allow remodelling and adaptation of the periodontium with the new tooth position. Rapid extrusion is associated with a risk that the periodontal ligament will be torn and that tooth ankylosis may occur.<sup>3</sup> Intense force can also lead to root resorption.<sup>4</sup> However, this latter phenomenon remains very limited if the forces, even if intense, are appropriately controlled.<sup>5</sup>

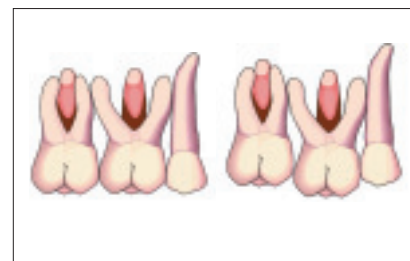
### Indications for Orthodontic Extrusion

Orthodontic extrusion is indicated in the following situations (**Fig. 1**):

- for treatment of a subgingival or infraosseous lesion of the tooth between the cemento-enamel junction and the coronal third of the root (e.g., caries, oblique or horizontal fractures, perforations caused by a pin or post, internal or external root resorption), especially when there are esthetic considerations
- for treatment of a restoration impinging on the biological width
- for reduction of angular bone defects and isolated periodontal pockets<sup>6</sup>



**Figure 1:** Examples of indications for orthodontic extrusion: a) subgingival or infraosseous dental lesion, such as a fracture; b) restoration impinging on the biological width; c) reduction of localized angular bone defects; d) preimplant extraction; e) trauma or impacted teeth.



**Figure 2:** Root proximity, a major contraindication for orthodontic extrusion of a molar.

- for preimplant extraction to maintain or re-establish the integrity of an alveolar ridge (see “Extrusion for Implant Purposes”)
- for orthodontic extraction where surgical extraction is contraindicated (e.g., in patients receiving chemotherapy or radiotherapy)<sup>7</sup>
- for treatment of trauma<sup>8,9</sup> or impacted teeth<sup>10</sup> (canines).

### Contraindications to Orthodontic Extrusion

Extrusion is contraindicated in patients with the following conditions:

- ankylosis or hypercementosis<sup>11</sup> (the extra load would cause intrusion of the anchor teeth)
- vertical root fracture
- root proximity and premature closure of embrasures (**Fig. 2**).

Additional contraindications come into play when extrusion is used for prosthetic purposes:

- short roots, which do not allow for adequate support of the restoration<sup>12</sup> (that is, when the crown–root ratio is less than 1:1)
- insufficient prosthetic space
- exposure of the furcation.

These criteria are not absolute and do not apply if the purpose of orthodontic extrusion is to increase the quantity of bone in a ridge before placing a dental implant.

### Advantages

Orthodontic extrusion is a conservative procedure that allows retention of a tooth without the disadvantages of a fixed bridge (e.g., the mutilation of adjacent dental tissue that typically occurs during bridge fabrication). As well, extrusion does not involve loss of bone or periodontal support, as commonly occurs during extraction. Simple surgical crown lengthening involves additional resection of bone of the teeth adjacent to the tooth that is to be lengthened, and such osteotomy can sometimes be avoided by use of orthodontic extrusion. Finally, this simple technique requires a relatively easy movement of the tooth.

### Disadvantages

Wearing an orthodontic device, as is required for orthodontic extrusion, may cause esthetic problems and may adversely affect oral hygiene. As well, the duration of treatment (4 to 6 weeks of extrusion and 4 weeks to 6 months of retention for implant cases in which tissue and bone remodelling are the objectives<sup>6</sup>) may discourage some patients. Indeed, some authors recommend 4 weeks of retention for every millimetre of extrusion.<sup>4</sup> At the end of the procedure, conservative periodontal surgery may be necessary to correct any discrepancy that has developed between adjacent periodontal levels.<sup>13</sup>

### Forces Exerted

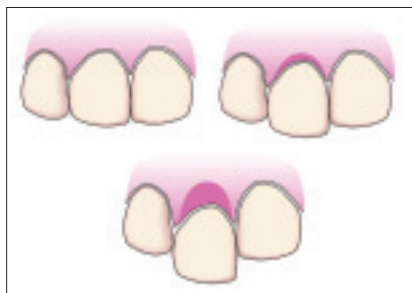
Forces of 15 g for the fine root of a lower incisor and 60 g for a molar are sufficient for slow extrusion. Some authors recommend that the maximum force for a slow movement should not exceed 30 g,<sup>4,14</sup> whereas rapid extrusions are accomplished with forces higher than 50 g.<sup>15</sup>

After a latency period of a few days to a few weeks, including a period of hyalinization, slow extrusion occurs at a rate of approximately 1 mm or less per week.<sup>4</sup> The force used will vary depending on the physiologic response of the patient and other factors such as root surface morphology. The extent of the force exerted can only be approximated, since it is difficult to quantify the force applied. The forces must be adjusted on the basis of the clinically verified speed of extrusion.

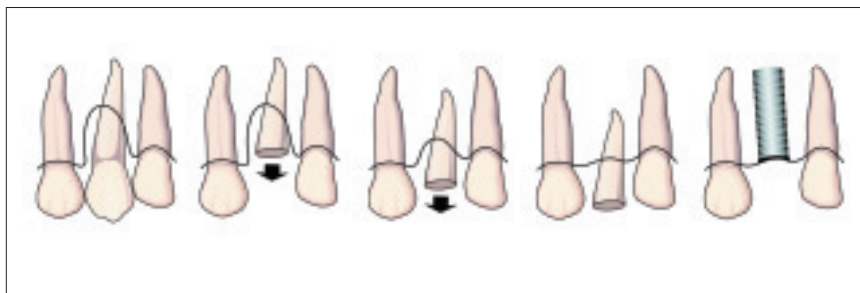
It is imperative that constant force be maintained between the extrusion and hyalinization phases; otherwise, the desired orthodontic movement will not take place. Periodontal ligament tension is needed for bone remodelling and movement of the periodontal attachment.<sup>8</sup> Finally, the force must be applied along the tooth axis to prevent any undesirable tilting.

### Periodontal Effects

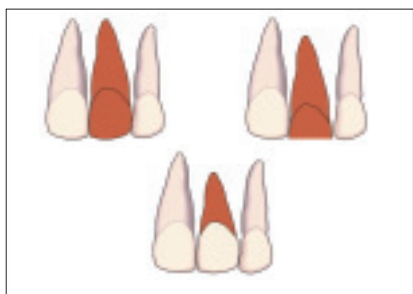
Orthodontic extrusion forces coronal migration of the root and increases the bone ridge as well as the quantity of attached gingiva, in particular when weak to moderate forces are applied.<sup>16,17</sup> The amount of attached gingiva is



**Figure 3:** Development of a band of immature nonkeratinized tissue ("red patch").



**Figure 4:** Steps in orthodontic extrusion for the purpose of preimplant extraction.



**Figure 5:** Restoration phase. Care is needed to prevent overcontouring of the crowns.

increased through eversion of the sulcular epithelium, appearing first as immature nonkeratinized tissue (known as "red patch") (Fig. 3) and then as keratinized tissue; the process of keratinization requires 28 to 42 days.<sup>4</sup> After coronal movement of the periodontal attachment has occurred, minor surgical correction may be necessary. To avoid or minimize this correction, some authors recommend weekly fibrotomy (incision of the supracrestal gingival fibres).<sup>18,19</sup> Others recommend a single fibrotomy procedure when the movement is completed,<sup>5,17</sup> before bone and gingiva remodelling occurs. However, according to several clinicians, fibrotomy has proved unpredictable, and gingiva and/or bone remodelling may still be required after the stabilization period.<sup>1,20</sup> In a study carried out on dogs, repeated fibrotomy failed to prevent coronal migration of the gingival attachment.<sup>21</sup> In-depth studies on human subjects to demonstrate the usefulness of this procedure and to define the appropriate frequency have yet to be carried out.<sup>5</sup>

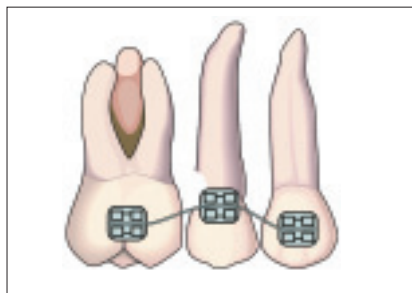
### Extrusion for Implant Purposes

Orthodontic extrusion, which preserves or regenerates the volume of bone in the ridge, makes the placement of dental implants more favourable. Conservation of the ridge allows placement of the dental implant within the thickness of the bone in a suitable axis. It also optimizes the potential for a guided bone regeneration technique.<sup>7</sup> Finally, the newly keratinized tissue improves the esthetic appearance at the site.<sup>22</sup> More specifically, extrusion is appropriate for

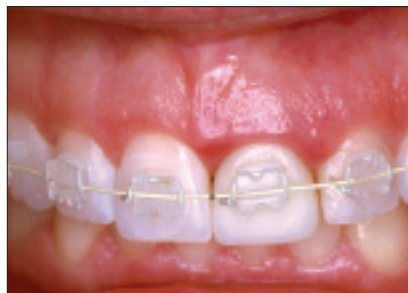teeth with average bone loss and when esthetics is a determining factor (Fig. 4), because it facilitates esthetic corrections and ensures stabilization of the implant within adequate bone mass.<sup>23</sup> The eruptive phase, lasting between 4 and 6 weeks, is followed by 6 to 8 weeks of stabilization, during which tissues are remodelled before extraction of the "condemned" tooth and placement of the dental implant.<sup>7</sup> However, some authors recommend up to 6 months of retention in preimplant cases to maximize remodelling of the ridge.<sup>6</sup> Indeed, prolonged stabilization allows more time for tissue remodelling, which, in turn, promotes more voluminous bone remodelling and decreases the risk of relapse before placement of the dental implant.<sup>6</sup>

### Extrusion and Endodontics

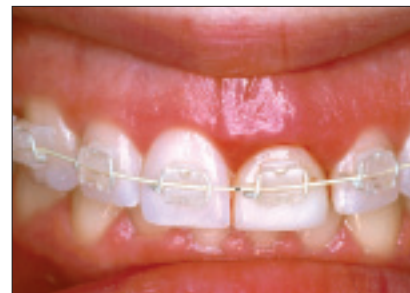In some cases, the tooth to be extruded must be treated endodontically to prevent sensitivity and exposure of the pulp during the occlusal reduction required during the extrusion.<sup>4</sup> A canal that cannot be adequately treated (because of subgingival fracture and lack of an adequate operative field) can be filled with calcium hydroxide before extrusion and subsequent treatment.<sup>14</sup> However, when the tooth must be extracted and the purpose of extrusion is to obtain an optimal ridge (e.g., in cases of preimplant extraction), pulpectomy may be sufficient.<sup>15</sup> Moreover, if the tooth is to be saved and its pulp kept intact, slow orthodontic extrusion, over a period of 3 to 6 months, is the preferred method of reducing the risk of pulpal necrosis; rapid extrusion could be traumatic to the pulpal tissue.<sup>24</sup> A histologic study demonstrated odontoblastic degeneration after 1 week of activation and pulpal fibrosis after 4 weeks in a tooth subject to an extrusion force of 50 g.<sup>25</sup> The authors assumed that the pulpal reaction would differ depending on the diameter of the apical foramen. Pulp prolapse would be due to ischemia secondary to rapid movement.<sup>25</sup> During rapid extrusion, a pseudo-apical lesion (an apical radiolucency) appears, which must be differentiated from a true lesion of endodontic origin. However, a tooth that has undergone incomplete root canal treatment, although asymptomatic, could eventually develop a true apical lesion because of inflammatory mediators involved in the root apex during orthodontic movement.<sup>26</sup>



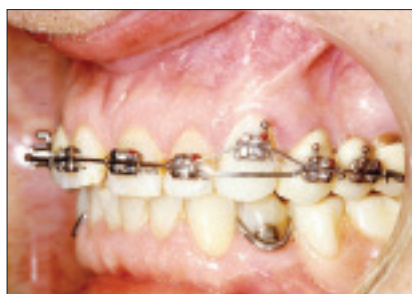**Figure 6a:** System of orthodontic brackets attached by a nickel-titanium wire



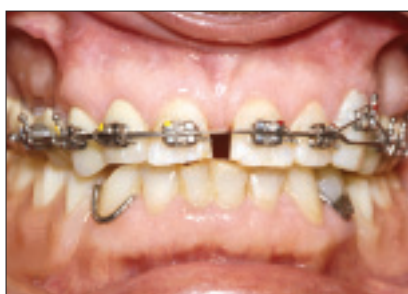**Figure 6b:** Extrusion is accomplished by the orthodontic brackets over a 1-month period.



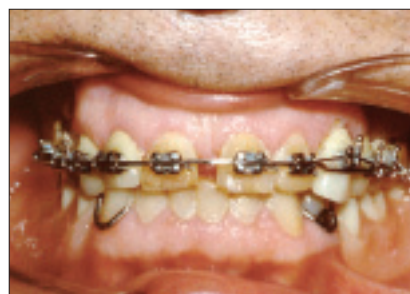**Figure 6c:** Coronal migration of the gingiva in the buccal aspect of extruded tooth 21. (Treatment by Dr. René Voyer.)



**Figure 7a:** Extrusion accomplished by treatment with a traditional orthodontic bracket.



**Figure 7b:** The stabilization wire is attached to the brackets adjacent to the tooth that is to be extruded.



**Figure 7c:** Active extrusion is carried out over a 1-month period. (Treatment by Dr. Martin Vallois.)

### Extrusion and Prosthodontics

The mesiodistal diameter of the root, which is naturally “strangled” at the cemento-enamel junction of single-rooted teeth, is reduced with progression of the extrusion (especially in the case of conical roots), which involves expansion of interproximal gingival embrasures. The contour shape of the crowns must not be exaggerated to compensate for this reduction in diameter (Fig. 5). Similarly, embrasures should not be filled to prevent an overcontour, which could adversely affect the marginal periodontium.<sup>27</sup>

### Techniques

Several extrusion methods are available, depending on the clinical conditions encountered. A variety of mechanical strategies can be used to control the forces applied.

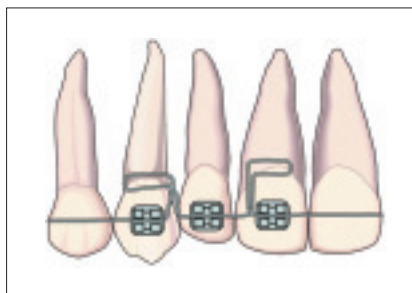
One technique involves placing orthodontic brackets on the buccal aspect of the teeth adjacent to the tooth that is to undergo extrusion in a passive position that will not cause any orthodontic movement of the anchor teeth. The bracket on the target tooth is positioned more apically than the brackets on the adjacent teeth; the difference in distance represents the desired extrusion. A 0.016-in. nickel-titanium arch wire is attached to the brackets (Figs. 6a, 6b and 6c). If greater movement is desired, a second, more rigid wire (0.016 in. x 0.022 in.), attached only to the brackets of the adjacent teeth, is used to stabilize everything (Figs. 7a, 7b and 7c). Following extrusion, a more rigid 0.018-in. stainless steel arch wire is inserted and set by means of a

metal ligature for a minimum retention period of 12 weeks.<sup>11</sup> If the dental tissues are inadequate for cementing a bracket, a composite reconstruction of the crown can be done or another consolidation strategy can be used.

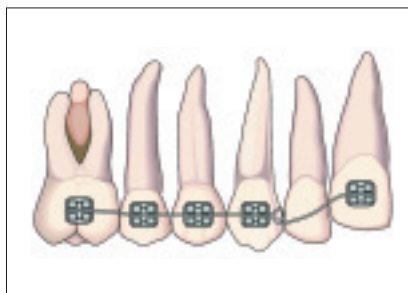
It is possible to avoid positioning the bracket apically by shaping a stainless steel wire (0.018 in. diameter) into a horizontal loop (Fig. 8). This activated extrusion system will produce movement of 1 mm per month. A wire in the form of a spiral (a spring) can also be used to provide the necessary traction force (Fig. 9).

Another strategy consists of inserting a rigid wire into the restorations of the anchor teeth. A metal wire, 0.7 mm in diameter, hooked at one end, is cemented into the canal of the tooth that is to undergo extrusion. An elastic connects the hook to the rigid anchor wire to activate the mechanism (Fig. 10). The elastic is changed every 2 weeks. This method can be difficult to use on posterior teeth because occlusion can interfere with the mechanism.

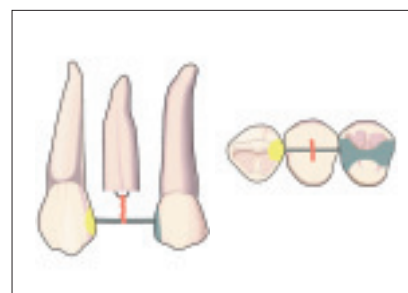
If the anchor teeth have not been restored, a rectangular stainless steel arch wire (0.018 or 0.019 in. x 0.025 in.) can be folded and affixed with composite to the buccal aspect of each tooth (Figs. 11a and 11b). Forces must be applied according to the position of the long axis of the tooth that is to undergo extrusion to prevent buccal or lingual tipping. A temporary crown cemented on a final post can be used as a traction attachment point; this approach maintains the esthetic appearance.<sup>3</sup> If necessary, the proximal contours of the tooth undergoing extrusion can be carefully reduced to prevent the



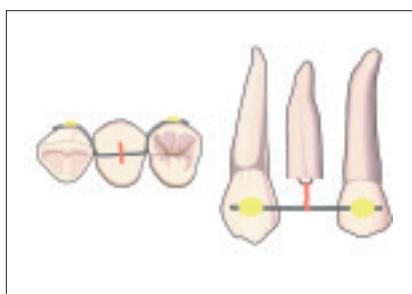
**Figure 8:** A system of orthodontic brackets attached by a horizontal loop wire.



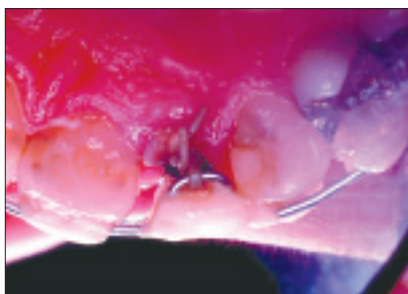
**Figure 9:** Extrusion of a central incisor affected by traumatic impaction is accomplished with an orthodontic bracket system activated by a spring.



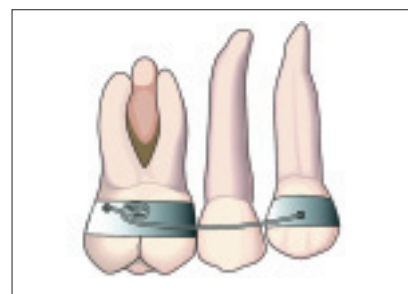**Figure 10:** Orthodontic wire embedded in the restorations adjacent to the tooth that is to be extruded. Movement is effected by an elastic that is changed regularly.



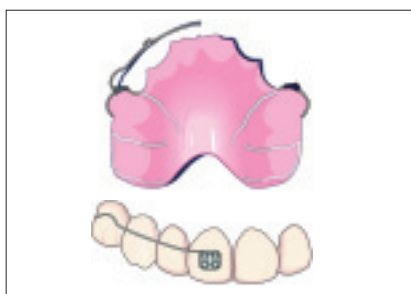**Figure 11a:** Orthodontic wire cemented by composite to the buccal aspect of the anchor teeth. An elastic activates the extrusion in the vertical axis only.



**Figure 11b:** The extrusion is accomplished by means of an orthodontic wire activated by an elastic. The temporary restoration in acrylic resin is cemented to the wire to improve the esthetic appearance. (Treatment by Dr. René Voyer.)



**Figure 12:** A spring welded to a band (molar anchor) can be used to activate extrusion of the first premolar.



**Figure 13:** Removable device (Hawley retainer with spring) and bracket on the tooth that is to be extruded.

tooth from interfering with the movement.

An extrusion device can also be prepared from a band and a soldered spring (Fig. 12); however, this method is more labour-intensive.

A removable Hawley device and an anchoring tip cemented to the buccal aspect is a good mechanical alternative (Fig. 13). This method is useful when the adjacent teeth are mobile or offer inadequate anchorage because of trauma or when mild force is required.

The number of teeth required for anchoring depends on the type of tooth to be extruded, root number and conformation, and the quantity of periodontal attachment. Follow-up evaluations should be done every 2 weeks to

ensure adequate oral hygiene and to correct any changes in occlusion as movement occurs. As well, it is important to ensure that movement of the tooth being treated actually occurs, because tooth ankylosis will cause the anchoring mechanism to be intruded.

### Evaluation and Preparation of Cases

Before any therapeutic decision can be made, a detailed dental history, including that of any potential dental trauma, must be obtained. The evaluation must also take into account oral hygiene; bacterial plaque control must be exceptional before starting orthodontic extrusion treatment, so as to reduce the risk of dental demineralization and periodontal inflammation, which would adversely affect marginal bone gain or induce hyperplasia of the soft tissues.

Before starting treatment, the dentist must evaluate the following:

- periodontal status
- quality and quantity of attached gingiva
- depth of periodontal (or gingival) pockets for the targeted teeth
- esthetic appearance of the site
- gingival clearance when smiling
- gingival contour line
- occlusion
- overjet and overbite

- interference with movement (occlusal excursion)
- postextrusion prosthetic space
- general condition of the dentition.

It is imperative to maintain an appropriate crown–root ratio (at least 1:1 after extrusion) and to ensure adequate width of the pulpal canal (a wide pulpal canal may indicate root fracture) so as to provide a favourable prognosis for the restored tooth. Periodontal probing, radiographic analysis and examination of the fragment of the fractured tooth (if available) can help in determining the extent of the fracture or carious lesion or in detecting a vertical root fracture.

The informed consent form must describe, among other items, the risks of ankylosis, root resorption, relapse, movement of adjacent teeth and failure of treatment, any of which could lead to extraction of the tooth and another treatment option, such as a dental implant or other prosthetic replacement. As well, the consent form should point out the advantages and disadvantages of each alternative solution, specifying the duration of therapy, the approximate number of visits required and the costs.

## Conclusions

In spite of the relative difficulties, orthodontic extrusion remains an accessible technique for general practitioners and a beneficial technique for the patient who wishes to keep a tooth, if only to keep the bone ridge volume intact and thereby to maximize the benefits of dental implants. ✦

**Acknowledgements:** *The authors wish to thank Dr. Sylvain Arsenault, director, department of stomatology, Notre-Dame Hospital, Montreal, Quebec; Dr. Fannie Brousseau, orthodontist, Rosemère, Quebec; Dr. Sylvain Gagnon, orthodontist, Montreal, Quebec; Dr. Martin Vallois, orthodontic resident, University of Montreal; and Danielle Mongrain, graphic artist, Notre-Dame Hospital, Montreal (Quebec).*



*Dr. Bach is clinical instructor at the University of Montreal, Montreal, Quebec. He also maintains a private practice in Montreal.*



*Dr. Baylard is lecturer and clinical instructor in the faculty of dentistry, University of Montreal, Montreal, Quebec. He also maintains a private practice in Montreal.*



*Dr. Voyer is assistant professor and director, division of clinical periodontology, faculty of dentistry, University of Montreal, Montreal, Quebec. He also maintains a private practice in Montreal.*

**Correspondence to:** Dr. Normand Bach, 12660 Odette Oligny, Montreal QC H4J 2R4. E-mail : [normbach@botmail.com](mailto:normbach@botmail.com).

*The authors have no declared financial interests.*

## References

1. Sabri R. L'allongement coronaire par l'égression orthodontique. Principes et techniques. *J Parodontol* 1989; 8(2):197–204.
2. Antrim DD. Vertical extrusion of endodontically treated teeth. *US Navy Med* 1981; 72:23–8.
3. Oesterle LJ, Wood LW. Raising the root. A look at orthodontic extrusion. *J Am Dent Assoc* 1991; 122(7):193–8.
4. Minsk L. Orthodontic tooth extrusion as an adjunct to periodontal therapy. *Compend Contin Educ Dent* 2000; 21(9):768–70, 772, 774.
5. Malmgren O, Malmgren B, Frykholm A. Rapid orthodontic extrusion of crown root and cervical root fractured teeth. *Endod Dent Traumatol* 1991; 7(2):49–54.
6. Mantzikos T, Shamus I. Case report: forced eruption and implant site development. *Angle Orthod* 1998; 68(2):179–86.
7. Buskin R, Castellon P, Hochstedler JL. Orthodontic extrusion and orthodontic extraction in preprosthetic treatment using implant therapy. *Pract Periodontics Aesthet Dent* 2000; 12(2):213–9.
8. Alves LD, Donnelly JC, Lugo A, Carter DR. Reeruption and extrusion of a traumatically intruded immature permanent incisor: case report. *J Endod* 1997; 23(4):246–8.
9. Jacobs SG. The treatment of traumatized permanent anterior teeth : case report & literature review. Part I — management of intruded incisors. *Aust Orthod J* 1995; 13(4):213–8.
10. Quiryryn M, Op Heij DG, Adriansens A, Opdebeeck HM, van Steenberghe D. Periodontal health of orthodontically extruded impacted teeth. A split-mouth, long-term clinical evaluation. *J Periodontol* 2000; 71(11):1708–14.
11. Nappen DL, Kohlan DJ. Orthodontic extrusion of premolar teeth: an improved technique. *J Prosthet Dent* 1989; 61(5):549–54.
12. Shillingburg HT. Fundamentals of fixed prosthodontics. 3rd ed. Carol Stream (IL): Quintessence Publishing; 1997.
13. Heithersay GS, Moule AJ. Anterior subgingival fractures : a review of treatment alternatives. *Aust Dent J* 1982; 27(6):368–76.
14. Reitan K. Clinical and histological observations on tooth movement during and after orthodontic treatment. *Am J Orthod* 1967; 53(10):721–45.
15. Bondemark L, Kurol J, Hallonsten AL, Andreason JO. Attractive magnets for orthodontic extrusion of crown-root fractured teeth. *Am J Orthod Dentofacial Orthop* 1997; 112(2):187–93.
16. Rosenberg ES, Cho SC, Garber DA. Crown lengthening revisited. *Compend Contin Educ Dent* 1999; 20(6):527–32, 534, 536–8.
17. Ainama J, Talari A. The increase with age of the width of attached gingiva. *J Periodontol Res* 1976; 11(4):182–8.
18. Palomo F, Kopezyk RA. Rationale and methods for crown lengthening. *J Am Dent Assoc* 1978; 96(2):257–60.
19. Lythgoe JR, Torabinejad M, Simon JH. Extrusion techniques for the general dentist. *Gen Dent* 1980; 28(1):42–3, 46–9.
20. Lovdahl PE. Periodontal management and root extrusion of traumatized teeth. *Dent Clin North Am* 1995; 39(1):169–79.
21. Berglundh T, Marinello CP, Lindhe J, Thilander B, Liljenber B. Periodontal tissue reactions to orthodontic extrusion. An experimental study in the dog. *J Clin Periodontol* 1991; 18(5):330–6.
22. Mantzikos T, Shamus I. Forced eruption and implant site development: soft tissue response. *Am J Orthod Dentofacial Orthop* 1997; 112(6):596–606.
23. Salama H, Salama M. The role of orthodontic extrusion remodeling in the enhancement of soft and hard tissue profiles prior to implant placement: a systematic approach to the management of extraction site defects. *Int J Periodontics Restorative Dent* 1993; 13(4):312–33.
24. Kahnberg KE. Surgical extrusion of root-fractured teeth — a follow-up study of two surgical methods. *Endod Dent Traumatol* 1988; 4(2):85–9.
25. Mostafa YA, Iskander KG, el-Mangoury NH. Iatrogenic pulpal reactions to orthodontic extrusion. *Am J Orthod Dentofacial Orthop* 1991; 99(1):30–4.
26. Blase D, Bercy P. Une technique esthétique d'allongement de la couronne clinique. L'égression orthodontique rapide. *Rev Belge Med Dent* 1993; 48(3):9–28.
27. Cronin RJ, Wardle WL. Prosthodontic management of vertical root extrusion. *J Prosthet Dent* 1981; 46(5):498–504.