

# Hard Tissue Pediatric Facial Trauma: A Review

Nicholas J.V. Hogg, MD, DDS, MSc, FRCD(C); Bruce B. Horswell, MD, DDS, MS, FACS

## Contact Author

Dr. Hogg  
Email: [n\\_hogg@yahoo.com](mailto:n_hogg@yahoo.com)



## ABSTRACT

Although hard tissue injuries are uncommon in the pediatric patient, dentists may be involved in the initial assessment of these patients. In this paper, we review fractures of the facial skeleton with a focus on dentoalveolar injuries. Minimally displaced fractures in pediatric patients can be managed conservatively, while displaced fractures may require open approaches and rigid fixation. New fixation stratagems are presented, and possible facial growth disturbances resulting from trauma are discussed.

**MeSH Key Words:** child; facial bones/injuries; skull fractures/diagnosis; skull fractures/surgery

© J Can Dent Assoc 2006; 72(6):555-8  
This article has been peer reviewed.

Although uncommon in the pediatric patient, craniofacial fractures can occur in some of the millions of pediatric patients in Canada and the United States every year.<sup>1</sup> Dentists may be involved in the initial assessment of these patients and should be able to obtain a focused history and carry out a physical examination of the facial region. Dental professionals are often involved, as members of a comprehensive team, in the management of the facial trauma patient, especially those with fractures involving the mandible and maxilla with concomitant dental trauma. To be an effective member of the team, the dentist requires knowledge of the surgical procedures that may be needed.

Compared with soft tissue injuries, maxillofacial fractures are uncommon in patients under 5 years old; fewer than 1% of maxillofacial fractures occur in this age group.<sup>1,2</sup> This is likely due to multiple factors, including the flexibility of the facial skeleton, the small size of the facial sinuses, the presence of multiple fat pads, unerupted teeth that may buttress the bone and a high level of adult supervision.<sup>3</sup> Among adolescents, an increase in risk-taking behaviour and a reduction in parental supervision result

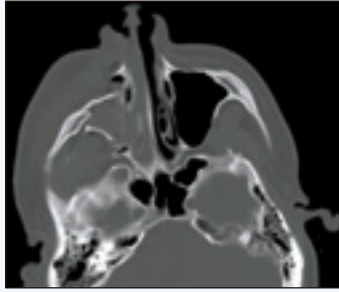
in an increase in the rate of facial fractures.<sup>1</sup> Still, the overall incidence of facial fractures in the pediatric population is less than 15% of all facial fractures.<sup>4</sup>

In this paper, we review fractures of the facial skeleton with a focus on dentoalveolar injuries. New fixation stratagems are presented, and possible facial growth disturbances resulting from trauma are discussed.

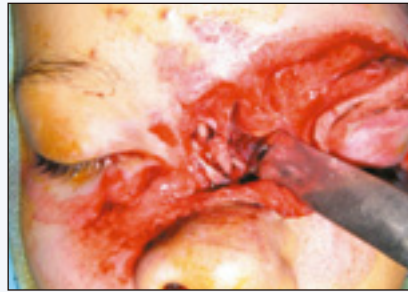
## Diagnosis

Physical examination plays an important role in the diagnosis of fractures of the facial skeleton. Children are more difficult to examine than adults, both physically and radiographically; because a thorough examination is essential, sedation should be considered if necessary.

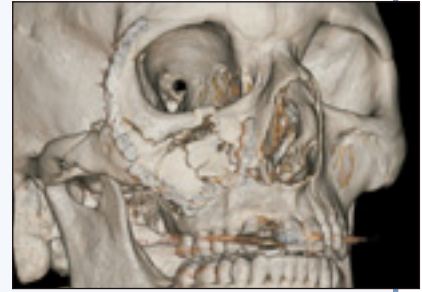Orbital examination should include assessment of visual acuity, pupil size and response, visual fields, diplopia (double vision), fundi and extraocular muscle function. Subconjunctival hemorrhage (bleeding under the bulbar conjunctiva) and chemosis (bulbar conjunctival swelling) are common in patients with periorbital fractures. Care must be taken not to miss diagnosing hyphema (blood in the anterior chamber of the eye) due to the possible



**Figure 1:** Posteriorly displaced zygoma fracture. Note the facial swelling on the affected side, which may mask the bony deformity beneath during visual inspection.



**Figure 2:** Facial laceration with comminuted nasal bone fracture sustained by an unrestrained passenger in a motor vehicle collision



**Figure 3:** Three-dimensional CT scan demonstrating reduction and fixation of a right zygoma fracture completed through multiple approaches.

long-term effects on vision. If there are any visual defects, consultation with an ophthalmologist is indicated. Palpation of the bony margins of the orbit for step deformities will indicate the point of fracture. Nasal examination should include an assessment of symmetry, dorsal deformity and intranasal obstruction.

The zygoma should be assessed for malar depression resulting in facial flatness on the affected side (Fig. 1). Paresthesia of the infraorbital nerve may result from bony impingement or direct nerve injury. Diplopia may occur as a result of swelling around the extraocular muscles or an increase in orbital volume with globe displacement. Posterior displacement (enophthalmos) or inferior displacement (hypophthalmos) of the globe, or both, can result from orbital floor disruption. Fractures of the zygomatic arch with consequent spasticity of the masseter muscle may cause trismus.

Examination of the maxilla and mandible involves assessment of occlusion and the dentition. Inspection of the occlusal plane for step deformities and of soft tissue for the presence of gingival tears as well as sublingual or vestibular ecchymosis can provide evidence of jaw fractures. It is important to locate missing teeth, as they may be present in orofacial wounds. A useful technique for obtaining a lateral view of the lips is to have the parent or child hold a periapical or occlusal film in place.

For imaging the mandible, panoramic radiography is a particularly valuable aid that provides good detail of all portions of the mandible, although supplementary perpendicular views may be needed to form an accurate diagnosis.

Modern computed tomography (CT) is the gold standard for viewing craniofacial fractures. CT images provide excellent detail of the cranium and mid-face structures and are also useful in imaging the mandibular condyle. Newer scanners provide a high level of detail in a short time and allow generation of 3-dimensional images, which are helpful in interpreting the patterns of complex fractures.

## Treatment

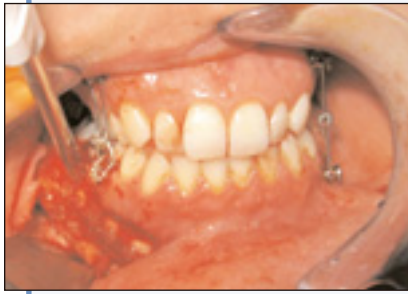Facial fractures can be managed by closed or open reduction. The type of fixation chosen depends on several factors: the age of the patient, the site of the fracture, the complexity of the injury and the approach that will be used to repair the fracture.<sup>1,2,5</sup>

### Mid-face Fractures

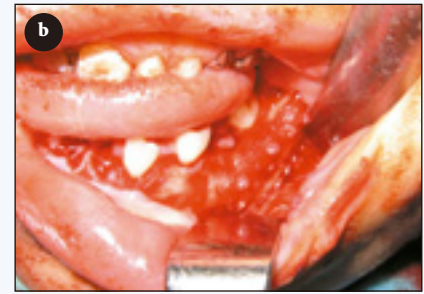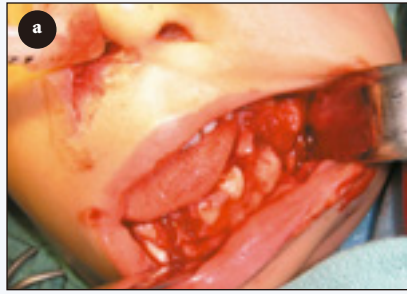Orbital and frontal bone injuries are uncommon in children, although, after age 7, the increasing prominence of the frontal bone in combination with the thinness of the anterior table of the frontal sinus makes fractures of the frontal sinus more common.<sup>5</sup> If the bones are displaced or extraocular muscle movement is restricted, an open approach, including consideration of a bicoronal flap to access the frontal bone, is recommended. Cosmetic incisions around and through the eyelids provide easy access to the fronto-orbital region. Patency of the nasofrontal ducts must be ensured if the frontal sinus is functional to prevent sinusitis or late mucocele formation.

Naso-orbito-ethmoid (NOE) fractures are among the most technically difficult fractures to correct. Consideration must be given to proper exposure and the use of resorbable fixation devices. The intercanthal distance (between the medial corner of each eye) must be re-established to prevent the development of traumatic telecanthus (widening of the canthi) postoperatively. Visual acuity and ocular mobility must be verified before the procedure and reconfirmed afterward.

Nasal injuries are among the most common injuries of the facial skeleton (Fig. 2). They can be difficult to assess in children due to edema and lack of cooperation during initial examination. Even when a closed approach is used, reduction of the nasal bones, alignment of the upper and lower cartilages and stabilization of the septum in the midline must be carried out with care. Septal hematomas must be evacuated with postoperative compression using septal splints to prevent recurrence of hematoma and subsequent growth disturbances.<sup>2,3</sup>



**Figure 4:** Maxillomandibular wire fixation in a 13-year-old patient with a right mandibular body fracture fixed with a resorbable plate.



**Figure 5:** Preoperative (a) and postoperative (b) views of resorbable fixation of a left mandibular body fracture in an 8-year-old patient.

Maxillary fractures are not common in children unless the maxillary sinus is present.<sup>5</sup> Closed reduction and maxillomandibular fixation for 2–3 weeks can be used to treat minimally displaced fractures. If open reduction is used, care must be taken to avoid damage to unerupted teeth from inappropriately placed screws.

Zygoma fractures are very rare in young children, but become more common as the zygoma becomes more prominent with growth.<sup>5,6</sup> Observation is indicated for “greenstick” and minimally displaced fractures. An intraoral approach can be used to access and reduce displaced arch fractures. Often a zygomatic buttress plate can be applied intraorally to manage an inferiorly and posteriorly displaced zygoma, which is a common pattern of displacement in children. Multiple approaches may be used to ensure adequate fixation in grossly displaced fractures (Fig. 3).

#### **Mandible Fractures**

Simple mandible fractures that are non-displaced or minimally displaced can be treated by closed reduction or observation. Mandibular fixation with an Erich arch bar or wire and composite cement can be used in young children. These patients can also be observed and managed with conservative treatment, including a soft diet and limitation of function for a short time.

Depending on the age of the patient, compliance and severity of the fracture, maxillomandibular fixation may be needed to ensure a stable occlusion (Fig. 4). This procedure has the disadvantages of occasionally limiting the ability to achieve anatomic reduction and restricting full motion of the mandible. Before age 2 and after age 6 years, children have a partial or mixed dentition, which makes the application of arch bars more difficult. If a malocclusion exists, elastics can be used for 10–14 days to guide and stabilize the occlusion.

Fractures that are displaced, open or unfavourable for healing may require open reduction and fixation (Fig. 5). Internal fixation requires an open approach, which may have deleterious effects on future growth. The need for

added stability of the fracture must be balanced against the risk of soft tissue scarring and disturbance of the periosteum, which may restrict bone growth.<sup>1</sup>

Condylar fractures in children are often amenable to conservative treatment, such as observation or closed reduction for a short period. If the patient is less than 5 years of age, the fracture will usually heal spontaneously, with little condylar remodelling. In 5–12 year olds, some bone remodelling occurs, but elastics may be required to allow mobility but help guide the occlusion. Children older than 12 years will have limited remodelling and will require elastics for 10–14 days followed by intense physiotherapy to regain mobility and function.<sup>7</sup> Consideration may be given to open reduction and fixation of displaced condylar–ramal fractures in adolescents to restore vertical height. Careful observation and a soft diet are critical in the management of mandibular condyle fractures.

#### **Dentoalveolar Injuries**

Avulsed or fractured primary teeth can be discarded or removed and plans made for space maintenance, if appropriate. Most dentoalveolar fractures should be manually reduced and stabilized with splints, composite cement or wires. Large bony segments may be effectively reduced in this manner if teeth are present or small fixation plates may be applied if the teeth are fractured. Oral soft tissue wounds, which may occur in conjunction with facial fractures, should be closed with resorbable sutures (fast-gut, gut or chromic). Tongue wounds, unless gaping or bleeding, do not usually require sutures. If closure is necessary, a slower resorbing, deep suture should be placed in the muscular layer.

#### **Rigid Fixation**

Resorbable fixation plates are now commonly used in addition to titanium mini- and micro-plates in the treatment of pediatric fractures.<sup>5</sup> The resorbable systems, which are made of copolymers of poly-L-lactic acid and polyglycolic acid, have varying strengths and rates of resorption but

most completely resorb by 1 year. Metallic fixation plates are still used due to their predictive nature and ease of handling.<sup>6</sup> Either type of fixation device is well tolerated by children.

### Growth Disturbances

Mid-face fractures can result in long-term skeletal deformities. NOE and severe nasal fractures can cause post-operative saddle-nose deformity or septal deviation.<sup>4</sup> They may also inhibit mid-face growth due to the complex relation between the ethmoid, vomer, septum and maxilla, and their contribution to facial projection.

Mandibular condylar fractures usually heal well in children, and a return to normal mandibular function may be quite rapid. However, parents must be informed of the risk of long-term growth restriction, which is more common in this type of fracture, particularly in early childhood. This may result in late malocclusion with deviation to the affected side, which may not be detected until the permanent dentition erupts.<sup>7</sup> Orthodontic treatment and surgery may be required to correct the occlusion once growth has been completed.

### Conclusions

Fractures in children are less common than soft tissue injuries due to multiple factors. Young children are more apt to have greenstick fractures and require observation or minimal fixation measures. Older children with comminuted or displaced fractures frequently require open reduction and fixation. Mandible fractures usually require a brief period of immobilization followed by physical therapy to reduce ankylosis and loss of function. Growth disturbances often occur in the actively growing child who has sustained trauma to the nasal and condylar regions. ➤

### THE AUTHORS



*Dr. Hogg is craniofacial surgery fellow in the department of surgery, Charleston Area Medical Center, Charleston, West Virginia.*



*Dr. Horswell is director of the First Appalachian Craniofacial Deformity Specialists, at the Charleston Area Medical Center's Women and Children's Hospital, Charleston, West Virginia.*

*Correspondence to: Dr. Nicholas J.V. Hogg, Charleston Area Medical Center, Facial Surgery Center, Suite #302, 830 Pennsylvania Ave, Charleston, WV, 25302, USA.*

*The authors have no declared financial interests.*

### References

1. Haug RH, Foss J. Maxillofacial injuries in the pediatric patient. *Oral Surg Oral Med Oral Path* 2000; 90(2):126–34.
2. Gassner R, Tuli T, Hachl O, Moreira R, Ulmer H. Craniomaxillofacial trauma in children: a review of 3,385 cases with 6,060 injuries in 10 years. *J Oral Maxillofac Surg* 2004; 62(4):399–407.
3. Ferreira PC, Amarante JM, Silva PN, Rodrigues JM, Choupina MP, Silva AC, and others. Retrospective study of 1251 maxillofacial fractures in children and adolescents. *Plast Reconstr Surg* 2005; 115(6):1500–8.
4. Zimmerman CE, Troulis MJ, Kaban LB. Pediatric facial fractures: recent advances in prevention, diagnosis and management. *Int J Oral Maxillofac Surg* 2005; 34(8):823–33.
5. Eppley BL. Use of resorbable plates and screws in pediatric facial fractures. *J Oral Maxillofac Surg* 2005; 63(3):385–91.
6. Bos RR. Treatment of pediatric facial fractures: the case for metallic fixation. *J Oral Maxillofac Surg* 2005; 63(3):382–4.
7. Horswell B. Condylar fractures. In: Kelly JP, editor. OMS knowledge update. Vol. 1, part 2. Chicago: AAOMS Publications; 1995. Tra–83

**Septanest® articaine HCl, is now  
made in Canada by Canadians**

Septodont, a world renowned anaesthetic manufacturer, is proud to announce that Septanest, and several of its other Septodont brands are now being manufactured in Cambridge Ontario.

**Made by Canadians; made for Canadians**



**Septodont of Canada, Inc.**  
Distributors of Septodont and Novocol Products  
Cambridge, ON (800) 647-0643  
[www.septodont.ca](http://www.septodont.ca)