

Inferior Alveolar Nerve Injury Caused by Thermoplastic Gutta-Percha Overextension

(Lésion du nerf alvéolaire inférieur consécutive à un dépassement apical de la gutta-percha thermoplastique)

- Nick Blanas, DDS, FRCD(C) •
- Fritz Kienle, BDS, FCD(SA), FRCD(C) •
- George K.B. Sándor, DDS, MD, PhD, FRCD(C), FRCSC, FACS •

S o m m a i r e

Les lésions du nerf alvéolaire inférieur consécutives à un trauma aboutissant à une fracture du maxillaire inférieur sont bien documentées et constituent un risque bien connu lorsqu'on planifie des interventions chirurgicales pour le maxillaire inférieur dans la région du canal alvéolaire inférieur. Ces lésions sont rares après un traitement endodontique. Le présent article signale un cas de lésion du nerf alvéolaire inférieur ayant une double cause, c'est-à-dire à la fois thermique et pressionnelle. L'article passe en revue la pathogenèse d'une telle lésion et propose des solutions pour la prendre en charge.

Mots clés MeSH : gutta percha/adverse effects; mandibular nerve/injuries; root canal obturation/adverse effects

© J Can Dent Assoc 2004; 70(6):384-7
Cet article a été révisé par des pairs.

We have previously described¹ one of the few cases reported in the English language literature of the management of inferior alveolar nerve injuries secondary to the extrusion of thermoplastic endodontic filling materials into the inferior alveolar canal. The use of these materials is becoming more popular with practitioners who perform endodontic therapy, thus compressive and thermal nerve injury may be encountered more frequently. The difficulty of managing overextension or overfill lies in deciding whether to intervene surgically and determining the correct timing of the intervention. We now present a second case, in which nonsurgical management was employed for at least 12 months, as well as an algorithm for the rational management of these injuries.

Case Report

A 62-year-old woman was seen in our outpatient clinic regarding pain and numbness in her left lower lip and chin, which developed following endodontic therapy for her mandibular left first molar.

She had seen her family dentist approximately 1 month earlier regarding a toothache and had subsequently undergone

root canal therapy on tooth 36. The procedure, which apparently involved obturation with thermoplastic gutta-percha, seemed uneventful. No other specific details of the endodontic procedure were available to the authors. Prescriptions for antibiotics and analgesics were given after completion of the treatment. The patient became concerned when she noticed that, although the numbness in her tongue had subsided, the numbness in her gingiva, teeth, left lower lip and chin persisted. In addition, she felt as though the original toothache persisted. After 10 days, she returned to see her dentist, who reassessed her clinically and renewed her prescriptions.

Following another 2 weeks of continuing symptoms, she sought the advice of a second dentist, who promptly referred her to an oral and maxillofacial surgeon who imaged the area in question and informed the patient that gutta-percha had extruded through the apical foramen of the tooth and apparently entered the inferior alveolar canal. The surgeon extracted tooth 36 under local anesthesia.

When her symptoms persisted, the patient was referred to the Oral and Maxillofacial Surgery Service at Toronto General Hospital for further assessment and management. She reported that the pain was diminishing slowly, but the

numbness was unchanged. Her teeth in the third quadrant felt “wooden.” She complained of drooling and of difficulty applying lipstick.

The patient had a history of coronary atherosclerotic heart disease and was scheduled to undergo coronary artery bypass surgery in a few weeks. She was taking antihypertensive medications and acetylsalicylic acid (ASA) daily, but had no known drug allergies.

Examination showed evidence of altered sensation in the left lower lip from the midline to the commissure, extending upward to and including the vermilion of the lower lip and down to the inferior border of the mandible. She had greatly reduced cold, pinprick and light-touch detection and 2-point discrimination in the entire field in question.

Intraoral examination revealed normal sensation in the tongue and lingual gingiva and complete anesthesia of the labial gingiva from the mandibular left second bicuspid to the midline. The cranial nerves were otherwise unremarkable.

A panoramic radiograph taken by the initial treating oral and maxillofacial surgeon showed radiopaque material in the area of the inferior alveolar canal extending in a posterior direction from the apex of the socket of tooth 36 (Fig. 1).

Surgical debridement of the inferior alveolar canal and decompression of the inferior alveolar nerve was discussed at great length with the patient, who subsequently refused to undergo such treatment, not wanting to jeopardize her upcoming cardiovascular surgery. She did, however, agree to present for frequent follow-up appointments.

The patient was referred to a neurologist for further assessment and documentation of her altered sensation. The assessment confirmed our clinical findings.

She was seen in follow-up 5 months after her initial assessment, at which time she reported no change in her symptoms. Objective test results were also unchanged at this stage. A repeat panorex showed the position of the gutta-percha to be unchanged. The surgical options were again reviewed, but limited by the fact that 6 months of recovery were required following her cardiac surgery.

At the 9-month follow-up, the patient reported an improvement in her symptoms. Clinically, she showed an increased response to pinprick stimulation of the skin. The gingiva were unchanged. The risks and benefits of surgical intervention were again discussed, but this time the patient was advised to not have surgery.

At the 1-year follow-up appointment, the patient reported a tingling sensation throughout her gingiva and left lower lip. Objective test results were improved distal to the mandibular canine. There was no change in the skin or mucosa from the canine to the midline. Arrangements were made for the patient to be seen 1 year later.

Discussion

Thermoplastic gutta-percha obturation techniques may be valuable for certain well-defined indications during endodontic therapy.² However, practitioners must take care to ensure proper technique during both instrumentation and

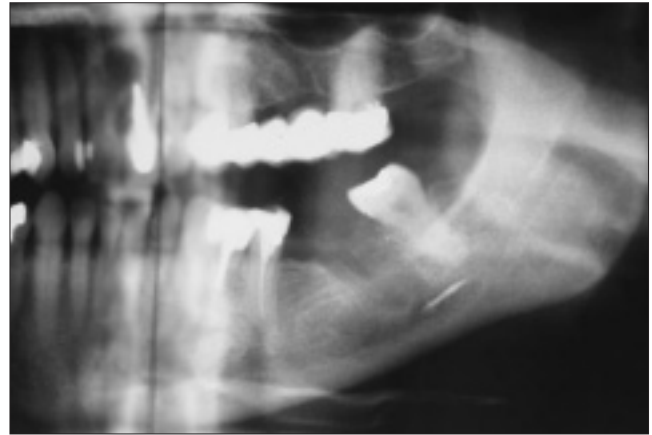


Figure 1: Panoramic radiograph showing radiopaque material in the inferior alveolar canal region.

obturation. There are numerous technical variations in the placement of warm gutta-percha,³ which may involve shaping the canal while preserving an apical constriction⁴ to prevent overextrusion of the obturation material. A master cone or a carrier may be prefitted to the canal,⁵ thus limiting the size of the apical constriction. This also helps to prevent overextension during the insertion of warm gutta-percha.

The excessive gutta-percha expressed through the apex in this case implies that a relative apical constriction was not present at the time of filling. This may be due to apical overinstrumentation. Another possibility is that the apical constriction was absent because the apex was wide open to begin with, although this seems doubtful given the patient's age. The root may have been split or cracked allowing extrusion through it as the root segments were spread apart by pressure during obturation, or excessive obturation pressure may have been used. Unfortunately, the extracted tooth was not available to the authors for examination.

Inferior alveolar nerve injuries caused by overextension of gutta-percha can be chemical or physical in origin. This obturation material is thought to be inert, minimizing the possibility of chemical injury. If a thermoplastic technique is used, the neurologic disturbance may be due to thermal damage as well as from mechanical compression of the nerve.

The temperature for softening thermoplastic gutta-percha ranges from 53.5° to 57.5° C⁶ and intracanal temperatures of 50–100° C have been reported.⁷ Because temperature elevations of as little as 10° C can cause bone damage and necrosis⁸ and nerve tissue is thought to be even more sensitive to thermal insult than bone,⁷ the mechanism of nerve injury is understandable with overfill or overextension of thermoplastic gutta-percha into the inferior alveolar nerve canal.

Classification schemes for such injuries may be useful, as they may help guide the practitioner in determining a prognosis for the injury and advising the patient. Two traditional classification schemes with applicability to mechanical nerve injuries have been described by Seddon and Sunderland.^{9–11} If the nerve injury in this case was solely due to mechanical causes, it could be classified as a neurotomesis

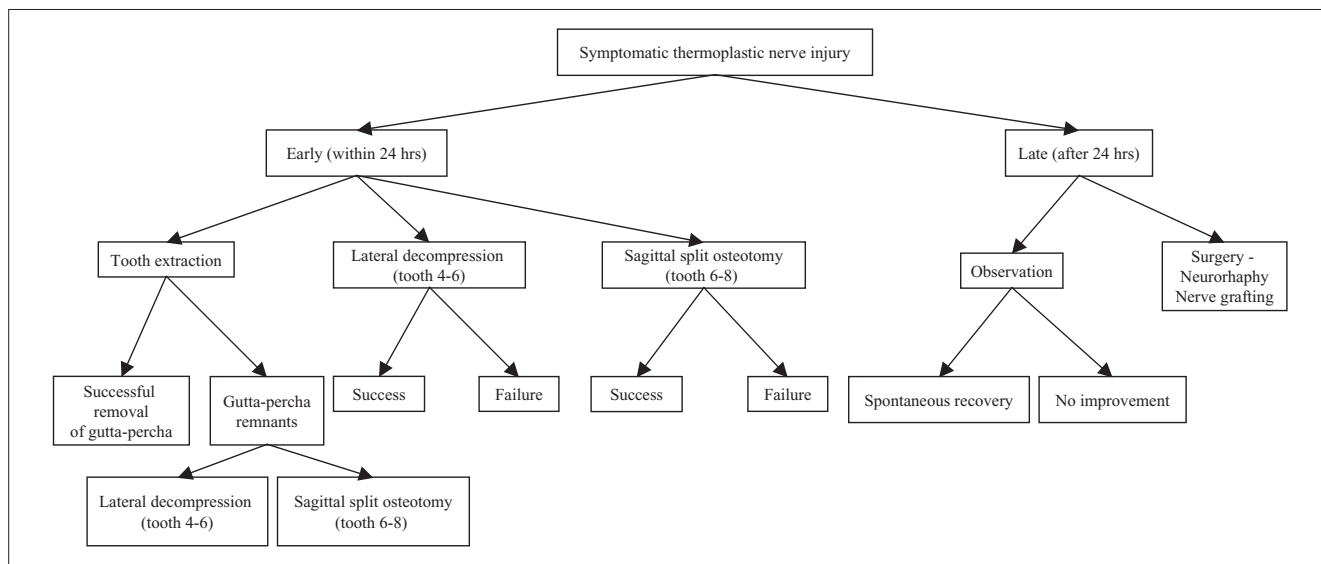


Figure 2: A suggested algorithm for the management of thermoplastic inferior alveolar nerve injuries.

(Seddon) or as a third, fourth or fifth degree injury (Sunderland). These injuries are characterized by a poor prognosis for recovery, as there is severe disruption of all of the components of the nerve trunk.¹¹⁻¹³ As a result of the poor prognosis and because of the possibility that a symptomatic neuroma will develop, surgical intervention is often considered in such cases.

The theoretical benefit of early surgical intervention and decompression of the nerve is the potential for the restoration of the neural microvasculature, possibly enhancing recovery of the nerve. However, there are definite risks of surgery, including nerve transection, as well as further nerve damage, which may lead to complete anesthesia or dysesthesia.

The possibility of microreconstructive surgery should also be explored. However, nerve grafting may cause bothersome paresthesia in the sensory distribution of the donor site nerve. Although the sural nerve and the greater auricular nerve may be considered as possible donor sites, the long-term sensory deficit resulting from the transplantation of these nerves may result in permanent numbness in their distributions in the lower extremity or the ear lobe.¹²

The current case illustrates the dilemma in deciding whether surgery is indicated, given that the exact etiology of the injury cannot be determined. Fanibunda and others⁷ have reported on early surgical intervention undertaken in a similar clinical situation with very limited success. Our previously reported case¹ describes equally poor outcomes with a nonsurgical course. In the current case, surgical options were initially limited by extraneous factors, such as the patient's cardiac status. The gradual improvement in the patient's clinical signs and symptoms, as well as the significant risks of surgery resulted in the decision by both patient and practitioners to maintain a nonsurgical course. Further improvement may occur, although the ultimate outcome cannot be predicted.

We propose the algorithm shown in Fig. 2 as a possible strategy for managing thermoplastic injuries of the inferior alveolar nerve. Unfortunately, the literature currently provides little guidance with respect to evidence-based decision making and treatment planning in this setting. Specific surgical approaches are selected on the basis of which offers the greatest access to affected nerve segments in the various areas of the inferior alveolar nerve as it courses through the mandible. In the mid-body of the mandible, in the premolar and first molar area, a lateral corticotomy may be desirable; whereas in the more posterior zones of the lower jaw, in the molar region, a sagittal split osteotomy may provide better access (Fig. 2). Not included in the algorithm are recommendations for dealing with painful dysesthesia. In these cases, surgical or pharmacologic treatment may ultimately be required.

Conclusions

It seems logical that if the only injury sustained by a nerve is compression, then surgery to remove the cause as early as possible could be beneficial. This may enhance the potential for reperfusion of the compressed nerve and improve its ability to recover. With the additional insult of a thermal injury, the extent of injury becomes difficult to determine clinically and the benefits of early surgical intervention are uncertain. More cases are needed to validate our proposed protocol for managing combined thermal and compression injuries of the inferior alveolar nerve.

Given the uncertainty and difficulty associated with its treatment, the most important lesson from this case is prevention of this type of nerve injury. Dentists and endodontists must be aware of the consequences of overextension or periapical extrusion of endodontic filling materials, particularly those that are thermoplastic. ♦



Le Dr Blanas est spécialiste en chirurgie buccale et maxillofaciale membre du personnel, Sunnybrook and Women's College Health Sciences Centre et Faculté de médecine dentaire, Université de Toronto, Toronto (Ontario).



Le Dr Kienle est spécialiste en chirurgie buccale et maxillofaciale membre du personnel, Hôpital Credit Valley et Faculté de médecine dentaire, Université de Toronto, Toronto (Ontario).



Le Dr Sándor est professeur agrégé et directeur du programme d'études supérieures en chirurgie buccale et maxillofaciale, Faculté de médecine dentaire, Université de Toronto, coordonnateur de la chirurgie buccale et maxillofaciale, Hôpital pour enfants et Centre pour enfants Bloorview MacMillan, Toronto (Ontario).

Écrire au : Dr George K.B. Sándor, Département de médecine dentaire, Hôpital pour enfants, S-527, 555, av. University, Toronto ON M5G 1X8. Courriel : george.sandor@utoronto.ca.

Les auteurs n'ont aucun intérêt financier déclaré.

Références

1. Blanas N, Kienle F, Sandor GK. Injury to the inferior alveolar nerve due to thermoplastic gutta percha. *J Oral Maxillofac Surg* 2002; 60(5):574-6.
2. Budd CS, Weller RN, Kulild JC. A comparison of thermoplasticized injectable gutta-percha obturation techniques. *J Endod* 1991; 17(6):260-4.
3. Amditis C, Blackler SM, Bryant RW, Hewitt GH. The adaptation achieved by four root canal filling techniques as assessed by three methods. *Aust Dent J* 1992; 37(6):439-44.
4. Musikant BL, Cohen BI, Deutsch AS. Simplified obturation of tapered canal preparations. *Compend Contin Educ Dent* 1998; 19(11):1152-5.
5. Valli KS, Rafeek RN, Walker RT. Sealing capacity in vitro of thermoplasticized gutta-percha with a solid core endodontic filling technique. *Endod Dent Traumatol* 1998; 14(2):68-71.
6. Cohen BD, Combe ED, Lilley JD. Effect of thermal placement techniques on some physical properties of gutta-percha. *Int Endod J* 1992; 25(6):292-6.
7. Fanibunda K, Whitworth J, Steele J. The management of thermomechanically compacted gutta percha extrusion in the inferior dental canal. *Br Dent J* 1998; 184(7):330-2.
8. Eriksson AR, Albrektson T. Temperature threshold levels for heat-induced bone tissue injury: a vital microscopic study in the rabbit. *J Prosthet Dent* 1983; 50(1):101-7.
9. Seddon HJ. Three types of nerve injury. *Brain* 1943; 66:237-88.
10. Sunderland S. A classification of peripheral nerve injuries producing loss of function. *Brain* 1951; 74(4):491-516.
11. Mackinnon SE, Dellon AL. Surgery of the peripheral nerve. New York: Thieme Medical Publishers, 1988. p. 35-63.
12. Sunderland S. Nerves and nerve injuries. Part 1. 2nd ed. Edinburgh: Churchill Livingstone; 1978. p. 70.
13. LaBanc JP, Epker BN. Serious inferior alveolar nerve dysesthesia after endodontic procedure: report of three cases. *J Am Dent Assoc* 1984; 108(4):605-7.