

Congenital Maxillary Double Lip: Review of the Literature and Report of a Case

(Double lèvre supérieure congénitale : recensement de la littérature et rapport de cas)

- Wilson Denis Martins, DDS, PhD, OMFS •
- Fernando Henrique Westphalen, DDS, PhD •
 - Rodrigo Sandrin, DDS, MSc •
 - Eduardo Campagnoli, DDS, MSc •

S o m m a i r e

La double lèvre est une anomalie qui peut être soit congénitale soit acquise. Elle se manifeste le plus souvent à la lèvre supérieure, mais il arrive que les lèvres supérieure et inférieure soient toutes deux affectées. L'intervention chirurgicale (simple excision) produit de bons résultats fonctionnels et esthétiques. Dans le présent rapport, nous décrivons le cas d'une double lèvre supérieure congénitale, présentons un recensement de la littérature et discutons du diagnostic différentiel. La double lèvre intéresse particulièrement la dentisterie parce que le praticien généraliste est souvent le premier professionnel à repérer et à diagnostiquer cette affection rare.

Mots clés MeSH : adult; lip/abnormalities; lip/surgery

© J Can Dent Assoc 2004; 70(7):466-8
Cet article a été révisé par des pairs.

Double lip is an infrequent oral anomaly that may be acquired or congenital. More commonly affecting the upper lip,¹ it often takes the form of 2 masses of hyperplastic tissue on either side of the midline.² Double lip is caused by excessive areolar tissue and noninflammatory labial mucosa gland hyperplasia of the pars villosa.³ During smiling, the lip is retracted and the mucosa is positioned over the maxillary teeth, resulting in a “cupid’s bow” appearance. Double lip may require surgical correction for esthetic reasons. Treatment should be accomplished by excision of the mucosa and submucosal tissue, without involvement of the underlying muscle.^{4,5}

Case Report

A healthy 30-year-old woman was seen at the oral and maxillofacial clinic of the Pontifical Catholic University of Paraná in Curitiba, Brazil, for routine dental and oral examination. During the course of the examination, a unilateral extra fold of tissue in the form of a cupid’s bow was noted in the right upper lip (Fig. 1). The overlying mucosa was intact and appeared normal. There were no other associated congenital abnormalities.

The patient, who was wearing a full upper denture, stated that she had been aware of the anomaly before her teeth were extracted. She occasionally “sucked in” the extra tissue during times of stress. Although the condition bothered her, she had never been informed of the possibility of surgical correction. A provisional diagnosis of congenital unilateral upper double lip was made, and surgical excision was suggested to the patient.

Under local anesthesia (unilateral infraorbital nerve block), the mass was removed by transverse elliptical incision.^{1,6} The infraorbital nerve block was used to avoid distortion of the tissue mass. A light compression dressing was applied for 24 hours after the procedure. No postoperative problems occurred, and the cosmetic result was good (Figs. 2 and 3).

Histologic examination of the excised material revealed sections of soft tissue covered by stratified squamous epithelium with parakeratosis. Numerous minor salivary glands, with moderate lymphocytic infiltration, were present in the underlying connective tissue. A few muscle fibers were also present in the specimen (Fig. 4).

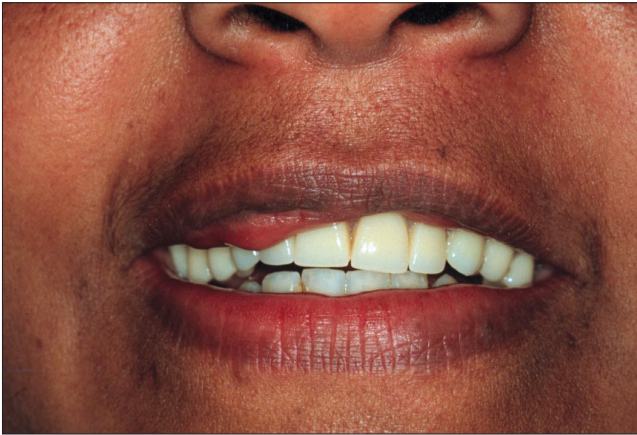

Figure 1: Initial aspect of the unilateral upper double lip.

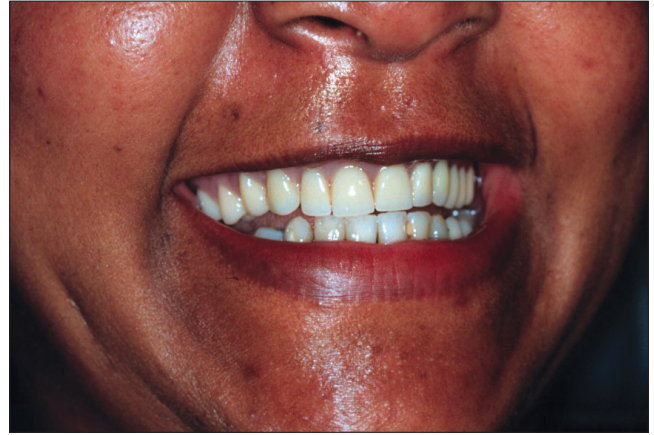

Figure 2: A 6-month follow-up photograph showing good esthetic result.

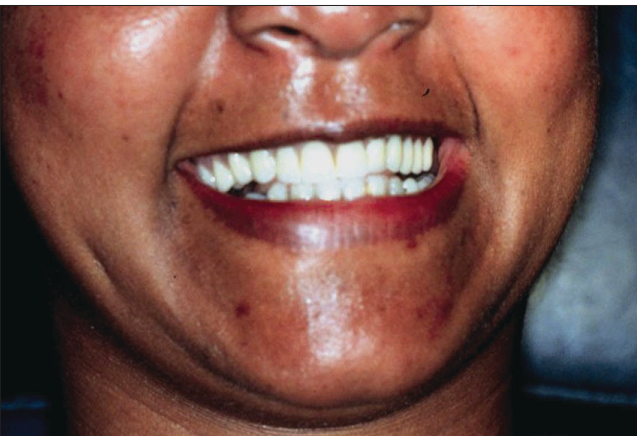

Figure 3: An 18-month follow-up photograph showing stable esthetic result.

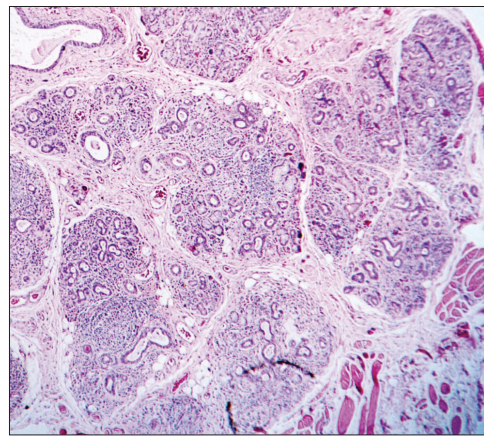


Figure 4: Microscopic aspect (hematoxylin and eosin, original magnification $\times 100$).

Discussion

Double lip consists of a fold of excess or redundant hypertrophic tissue on the mucosal side of the lip.^{2,7} It occurs most often bilaterally on the upper lip, but may be unilateral and can affect both lips.²

The condition, also referred to as macrocheilitis⁴ or hamartoma,⁸ has no predilection in terms of race or sex. The congenital form of double lip is thought to arise during the second or third month of gestation from a persistence of the sulcus between the pars glabra and the pars villosa of the lip.⁹ Although present at birth, the congenital condition may become apparent only after eruption of the teeth. Treatment of double lip is surgical and becomes necessary for cosmetic reasons, as in the present case, or if it interferes with speech or mastication. Recurrence has not been observed.⁹ In the current case, no recurrence occurred in over a year of follow up.

The acquired form of double lip may be secondary to trauma and oral habit, and may develop in association with Ascher's syndrome,^{2,7} which consists of the triad blepharochalasis, nontoxic thyroid enlargement and double lip. The first case of double lip and blepharochalasis was reported in 1909,² and the association of these findings with thyroid enlargement

was noted by Ascher.¹⁰ It is not clear whether thyroid enlargement is a consistent or necessary feature of the syndrome.³ The lip becomes enlarged in a manner suggestive of angioneurotic edema and, over time, this swelling partially resolves. Recurrences following surgical intervention have been noted.²

Another uncommon acquired condition is cheilitis glandularis, an inflammatory hyperplasia with varying degrees of inflammation of the lower labial salivary glands.⁷ The etiology of cheilitis glandularis is unknown, although familial inheritance and congenital predisposition, bacterial infection and irritation from sun, chemicals and tobacco have been advanced as causes.^{11,12}

The differential diagnosis of cheilitis glandularis and congenital double lip is important, because cheilitis glandularis has been associated with an increased risk of the development of squamous cell carcinoma.⁷ The differential diagnosis should also include vascular tumours, lymphangioma, angioedema, cheilitis granulomatosa, Miescher syndrome, mucocele, salivary gland tumours, inflammatory fibrous hyperplasia, sardoidosis and plasma cell cheilitis.¹³

Several surgical techniques have been described to repair double lip: W-plasty,¹⁴ electrosurgical excision⁸ and

triangular excision.⁴ In the current case, good results were obtained with transverse elliptical excision.^{1,6}

In conclusion, treatment of congenital double lip is indicated when the excess tissue interferes with mastication or speech or leads to such habits as sucking or biting the redundant tissue or is of esthetic concern to the patient.

Double lip is of special interest in dentistry because the general practitioner is often the first professional to detect and establish the diagnosis of this uncommon condition. ♦



Le Dr Martins est spécialiste en chirurgie buccale et maxillofaciale et professeur de stomatologie à l'Université catholique pontificale de Paraná, Curitiba, Brésil.

Le Dr Westphalen est professeur de radiologie à l'Université catholique pontificale de Paraná, Curitiba, Brésil.

Le Dr Sandrin est étudiant de cycle supérieur au programme de stomatologie, Université catholique pontificale de Paraná, Curitiba, Brésil.

Le Dr Campagnoli est étudiant de cycle supérieur au programme de stomatologie, Université catholique pontificale de Paraná, Curitiba, Brésil.

Écrire au : Dr Wilson Denis Martins, Rua Republica do Libano, 462 - 82520-500, Curitiba - PR, Brazil. Courriel : wilson@rla01.pucpr.br.

Les auteurs n'ont aucun intérêt financier déclaré.

Références

1. Reddy KA, Rao AK. Congenital double lip: a review of seven cases. *Plastic Reconstr Surg* 1989; 84(3):420-3.
2. Barnett ML, Bosshardt LL, Morgan AF. Double lip and double lip with blepharochalasis (Ascher's syndrome). *Oral Surg Oral Med Oral Pathol* 1972; 34(5):727-33.
3. Gorlin RJ, Pindborg JJ, Cohen MM. Syndromes of the head and neck. 2nd ed. New York: McGraw-Hill; 1976. p. 253-5.
4. Lamster IB. Mucosal reduction for correction of a maxillary double lip. *Oral Surg Oral Med Oral Pathol* 1983; 55(5):457-8.
5. Epker BN, Wolford LM. Reduction cheiloplasty: its role in the correction of dentofacial deformities. *J Maxillofac Surg* 1977; 5(2):134-41.
6. Kenny KF, Hreha JP, Dent CD. Bilateral redundant mucosal tissue of the upper lip. *J Am Dent Assoc* 1990; 120(2):193-4.
7. Cohen DM, Green JG, Dieckmann SL. Concurrent anomalies: cheilitis glandularis and double lip. Report of a case. *Oral Surg* 1988; 66(3):397-9.
8. Peterson A. Electrosurgical correction of maxillary double lip. *Den Dig* 1972; 78(3):182-8.
9. Rintala AE. Congenital double lip and Ascher syndrome: II. Relationship to the lower lip sinus syndrome. *Br J Plast Surg* 1981; 34(1):31-4.
10. Gorlin RJ, Pindborg JJ, Cohen MM. Syndromes of the head and neck. 2nd ed. New York: McGraw-Hill; 1964. p. 186-9.
11. Weir TW, Johnson WC. Cheilitis glandularis. *Arch Dermatol* 1971; 103(4):433-7.
12. Doku HC, Shklar G, McCarthy PL. Cheilitis glandularis. *Oral Surg Oral Med Oral Pathol* 1965; 20(5):563-71.
13. Wood NK, Goaz PW. Differential diagnosis of oral lesions. St. Louis: CV Mosby; 1985. p. 162-9.
14. Guerrero-Santos J, Altamirano JT. The use of W-plasty for the correction of double lip deformity. *Plat Reconstr Surg* 1967; 39(5):478-81.