

# Mandibular Premolar Impaction: 2 Case Reports

Clare McNamara, *BDentSc, MFDS, RCS(Eng), MFDS RCS(Irl)*;  
Timothy G. McNamara, *BDS, FDS, FFD, DOrth, FICD*

## Auteurs-ressource

Dre McNamara  
Courriel :  
[Clare.McNamara@bristol.ac.uk](mailto:Clare.McNamara@bristol.ac.uk)



## SOMMAIRE

Cet article passe en revue les principes de la prise en charge de prémolaires inférieures incluses et les facteurs qui contribuent au succès du traitement. Bien que la nature du traitement puisse dépendre de l'âge du patient, de ses antécédents dentaires, de la gravité de l'inclusion, du développement dento-alvéolaire et de la forme de la racine, les 2 études de cas présentées montrent qu'une issue favorable du traitement est possible, même dans les conditions les plus difficiles.

**Mots clés MeSH :** bicuspid/pathology; mandible; tooth, impacted/therapy; tooth, unerupted/therapy

© *J Can Dent Assoc* 2005; 71(11):859–63  
Cet article a été révisé par des pairs.

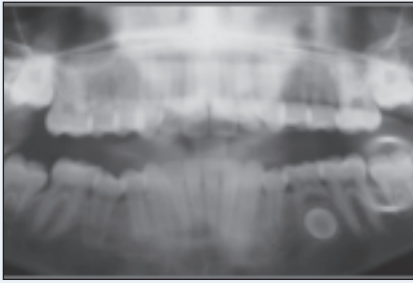
An impacted tooth is one that is embedded in the alveolus so that its eruption is prevented or the tooth is locked in position by bone or the adjacent teeth.<sup>1</sup> Mandibular second premolars rank third — after third permanent molars and maxillary permanent canines — in frequency of impaction.<sup>2</sup> The prevalence of impacted premolars has been found to vary according to age.<sup>3</sup> The overall prevalence in adults has been reported to be 0.5% (the range is 0.1% to 0.3% for maxillary premolars and 0.2% to 0.3% for mandibular premolars).<sup>3,4</sup> Premolar impactions may be due to local factors such as mesial drift of teeth arising from premature loss of primary molars; ectopic positioning of the developing premolar tooth buds; or pathology such as inflammatory or dentigerous cysts. They may also be associated with over-retained or infraocclusal ankylosed primary molars or with syndromes such as cleidocranial dysostosis.<sup>5–10</sup>

The cases described below illustrate the inherent potential for even the most unfavourably impacted mandibular premolars to respond well to treatment. Both patients

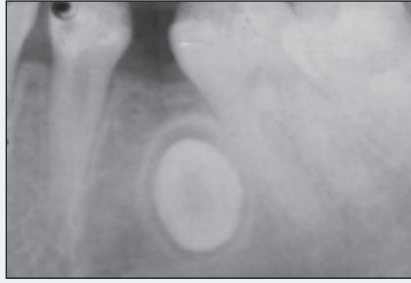presented with impactions of mandibular premolars that were technically demanding to manage, required considerable root torque control and were uncertain in their treatment outcome. The option of simply extracting the impacted premolars was not available, given the presenting malocclusion in case 1 and the multiple extractions already experienced in case 2. Both patients were treated with a combination of orthodontic relocation following conservative surgical exposure of the impacted premolars.

### Case 1

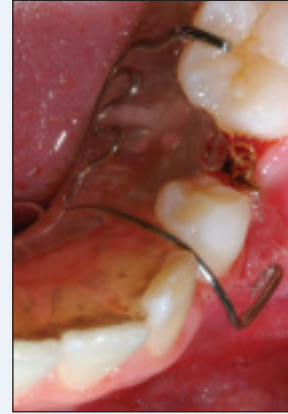A young girl, aged 11 years, presented with a Class II division I malocclusion. Her medical and dental history were not significant. She had been referred for orthodontic treatment following a routine examination by her general dental practitioner. She had no history of dental extractions or orthodontic treatment. Clinical examination revealed that all primary teeth, excluding the mandibular second primary molar, had exfoliated. Radiographs confirmed the presence of all permanent teeth, excluding the maxillary left third molar. The mandibular left second premolar was transversely impacted (Figs. 1a and 1b).



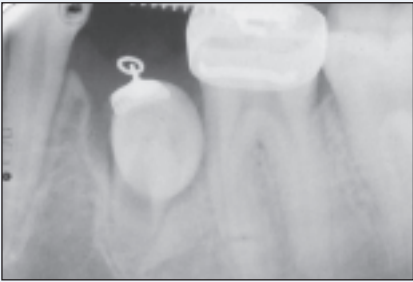**Figure 1a:** Orthopantomograph of 11-year-old patient at initial presentation.



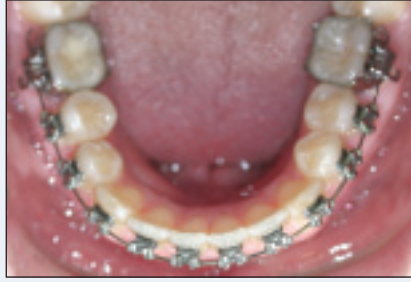**Figure 1b:** Periapical radiograph of the transversely impacted mandibular left second premolar at initial presentation.



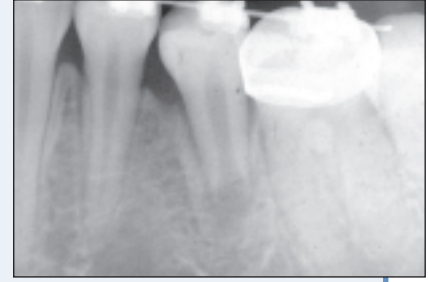**Figure 1c:** Occlusal view of patient at 12 years of age, at initial orthodontic relocation of the impacted mandibular left second premolar using a removable appliance with elastomeric traction and a bonded eyelet on the unerupted premolar.



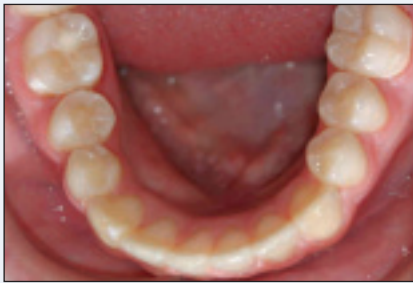**Figure 1d:** Radiographic view of patient at age 12 years 4 months. A fixed orthodontic appliance is now in situ and root development of the impacted premolar is progressing normally.



**Figure 1e:** Occlusal view of patient at age 13 years 3 months. The orthodontic relocation and alignment of the transversely impacted mandibular left second premolar is near completion.



**Figure 1f:** Radiographic view of patient at age 13 years 3 months, showing continued normal root development of the formerly transversely impacted mandibular left second premolar.

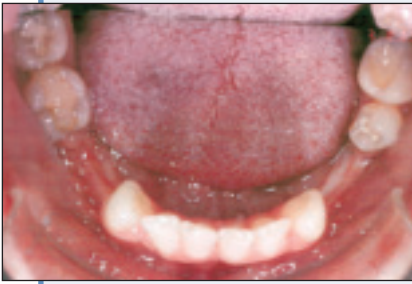

**Figure 1g:** Occlusal view of patient, age 13 years and 7 months, at debonding.

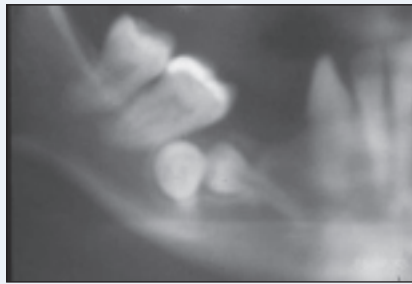
cally assisted eruption of this tooth. A surgical closed-flap eruption procedure was carried out under local anesthesia. An orthodontic eyelet, with gold chain, was bonded to the premolar at the time of surgery. A simple removable appliance was then used to commence traction of the impacted premolar using elastomeric chain attached to the gold chain (Fig. 1c). After 3 months, the removable appliance was replaced by a conventional fixed orthodontic appliance. Alignment of the impacted premolar was completed without complication (Figs. 1d to 1g). Total orthodontic treatment time was 19 months. Normal premolar root development is continuing (Fig. 1e) and progress is reviewed annually.

## Case 2

A woman aged 33 years, presented for orthodontic treatment of a Class II division I malocclusion complicated by the presence of 3 impacted mandibular premolars. She had no significant medical history. Her dental history was significant



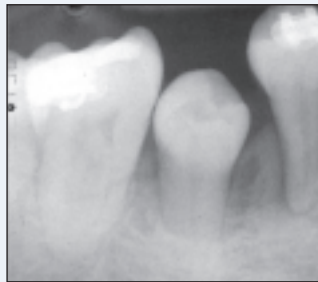
**Figure 2a:** Occlusal mandibular view of 33-year-old patient at initial presentation. Note the lack of dentoalveolar development in both mandibular buccal quadrants associated with early loss of permanent molars and the impaction of 3 premolars.



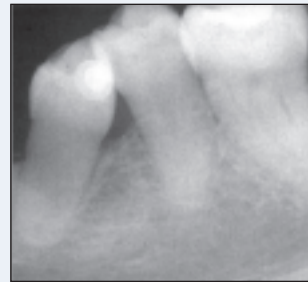
**Figure 2b:** Radiographic view of both right mandibular premolar impactions at initial presentation.



**Figure 2c:** Radiographic view of the left mandibular first premolar impaction at initial presentation.



**Figure 2d:** Radiographic view of patient, age 40 years, 4 years after orthodontic relocation of the mandibular right first premolar and 7 years after initial presentation. Note no orthodontic force has yet been applied to the formerly transversely impacted second premolar, which erupted spontaneously.



**Figure 2e:** Radiographic view of patient, age 40 years, 4 years after the mandibular left first premolar was orthodontically relocated.

as it included several extractions in childhood. She had no history of orthodontic treatment. Radiographs confirmed the presence of all permanent teeth excluding the 4 first permanent molars and the mandibular left second permanent molar. They also revealed the presence of 3 severely impacted mandibular premolars. Alveolar bone development was diminished in both mandibular premolar areas with tilting of adjacent teeth into these sites. In all 3 impacted premolars, root formation was complete. Adding to the complexity of the situation, the mandibular right second premolar was transversely impacted (Figs. 2a to 2c).

Treatment outcome was uncertain due to the degree of impaction, the completed root formation and the reduced level of available dentoalveolar bone. The patient's age and lack of growth potential were further complicating factors. Orthodontic eruption of the 2 mandibular first premolars was considered to be the most realistic objective. The position of the transversely impacted second premolar was so unfavourable that no orthodontic treatment of this tooth was envisaged and extraction was planned.

The same conservative surgical and orthodontic techniques used in case 1 were followed to align both impacted mandibular first premolars. Progress was slow but the patient's compliance and motivation were excellent. She insisted on continuing with orthodontic appliance therapy for 3 years. The prolonged duration of orthodontic treatment was the main operative complication in the management of this patient. Surgery was successful and no complications arose during or after the procedure.

After disimpaction and orthodontic eruption of the mandibular first premolars, no further orthodontic or surgical treatment was carried out. The patient was reviewed annually. The decision to extract the transversely impacted second premolar was abandoned. At the fourth yearly review appointment, with the patient 40 years of age and 7 years since her initial presentation, the impacted mandibular second premolar was found to have begun to erupt spontaneously in a lingual direction. In view of the patient's continued interest and motivation, further orthodontic

treatment has been resumed with a view to aligning this tooth (Fig. 2d).

## Discussion

Treatment options for impacted teeth include observation, intervention, relocation and extraction. On occasion, there may be some interaction between these treatment options.<sup>11</sup> Observation involves no treatment other than monitoring the patient clinically and radiologically. Generally it involves following a child or adolescent for a specific time, which can be divided into preimpaction and postimpaction periods. Intervention may involve simple extraction of a tooth or teeth, usually primary. Occasionally a permanent tooth extraction may be warranted depending on the etiology of the impaction and the specific tooth impacted. Intervention may include a brief period of orthodontic treatment to eliminate the impaction. Relocation refers to either surgical repositioning of the impacted tooth or, more commonly, orthodontic eruption of the impacted tooth. Orthodontic relocation, illustrated in both patients described above, may be more demanding in terms of time but results in fewer long-term complications.<sup>11,12</sup>

Kokich<sup>12</sup> describes the surgical and orthodontic management of impacted teeth and identifies the position and angulation of the impacted tooth, length of treatment time, available space and the presence of keratinized gingiva as critical factors that will affect prognosis and treatment outcome. Operational complications, none of which occurred in these 2 cases, include injury to adjacent periodontium, injury to adjacent teeth, nerve damage, multiple exposures of the impacted teeth and failure of the orthodontic bond when performing a closed-flap eruption procedure.<sup>2,11-13</sup>

Literature specific to impacted premolars is not extensive despite the fact that mandibular second premolars alone account for approximately 24% of all dental impactions.<sup>2,14</sup> In selecting an appropriate treatment option, the underlying etiological factors, space requirements, need for extraction of primary molars, degree of impaction and root formation of the impacted premolar should be considered. The option of simply monitoring<sup>14,15</sup> the impacted premolar proved unsuccessful in case 1 and was not feasible in case 2. Conservative surgical exposure of the impacted premolars with orthodontic traction and eruption<sup>16</sup> proved to be the most appropriate treatment option for these patients. Factors such as the patient's medical history, dental status, oral hygiene, functional and occlusal relationships and attitude toward and compliance with treatment will influence choice of treatment options.<sup>12,13</sup> Both patients were very compliant. Despite the poor childhood dental history of the patient in case 2, her attitude toward treatment and her motivation were excellent and proved central to the successful management of her difficult impactions.

In our literature review, we could not identify a report of an older patient. Successfully managed impacted premolar cases were most frequently reported in adolescents; the oldest patients were in their late twenties.<sup>5-7,14-19</sup> The patient in case 1,

who was 2 decades younger than the patient in case 2, fell within the age range most commonly reported. She presented with 2 additional features that may have contributed to her efficient management. Although the degree of transverse impaction in this patient was as marked as in case 2, delayed development, manifested by the immature premolar root form, may have been a contributory factor in the efficient alignment of her impacted premolar. Kokich<sup>12</sup> reported a similar severely impacted mandibular premolar with delayed root development, although his case was distally rather than transversely impacted. A second factor common to successfully managed cases is the presence of primary molars. Our 12-year-old patient had a primary molar in situ at presentation.

Operative orthodontic complications did not arise in either patient. The eyelets bonded at surgery functioned successfully and were later replaced without complication with conventional orthodontic brackets. The premolar roots, even in case 1 where the root form was immature, reacted favourably to orthodontic forces. In both patients, the impacted premolars retained their vitality and no external root resorption occurred despite the distances through which they were moved. The prolonged duration of treatment in case 2 did not adversely affect outcome. The significant difference between the patients related to dentoalveolar development and growth potential. The patient in case 1 had all the inherent growth potential commensurate with her age, enabling normal dentoalveolar development. Thus complete alignment of the transversely impacted mandibular premolar was possible. The absence of growth potential, together with the disruption of the dentoalveolar bone formation by multiple childhood extractions in the older patient could not be surmounted. Complete orthodontic alignment of the first premolars was not possible although their relocation improved dentoalveolar bone height and the recent spontaneous eruption of the mandibular second premolar has further improved dentoalveolar bone development in the right quadrant (Figs. 2d and 2e).

Common to both patients, the severity of the impactions contributed to the uncertainty of treatment outcome. Andreasen<sup>3</sup> suggests that surgical exposure should be confined to cases, both maxillary and mandibular, with no more than 45° of tilting and limited deviation from the normal position. Both patients' impactions fell well outside these guidelines. These case reports suggest that the degree of premolar impaction, the long-term loss of primary teeth, the lack of dentoalveolar bone and root form are not definitive obstacles to the disimpaction and relocation of impacted mandibular premolars.

## Conclusions

These 2 case reports illustrate the tremendous potential for treating impacted mandibular premolars, even under the most unfavourable circumstances. Patient age, early loss of primary and permanent molars, disruption to dentoalveolar

bone development, severity of impaction, premolar root form at presentation: none of these factors proved an obstacle to successful treatment. Critical to both patients' management was good compliance and motivation. ♦

## THE AUTHORS



*Dr. C. McNamara is senior house surgeon in the department of oral and maxillofacial surgery, Frenchay Hospital, Bristol, U.K.*



*Dr. T. G. McNamara is consultant orthodontist, Health Service Executive, Limerick, Ireland.*

*Correspondence to: Dr. Clare McNamara, Eastgate House, Lock Quay, Limerick, Ireland. E-mail: [Clare.McNamara@bristol.ac.uk](mailto:Clare.McNamara@bristol.ac.uk)*

*The authors have no declared financial interests.*

## References

- Dorlands' illustrated medical dictionary. 25th ed. Philadelphia: WB Saunders; 1974. p. 767.
- Alling CC 3rd, Catone GA. Management of impacted teeth. *J Oral Maxillofac Surg* 1993; 51(1 Suppl 1):3–6.
- Andreasen JO. The impacted premolar. In: Andreasen JO, Petersen JK, Laskin DM, editors. Textbook and color atlas of tooth impactions; diagnosis, treatment and prevention. Copenhagen: Munksgaard; 1997. p. 177–95.
- Oikarinen VJ, Julku M. Impacted premolars. An analysis of 10,000 orthopantomograms. *Proc Finn Dent Soc* 1974; 70(3):95–8.
- Burch J, Ngan P, Hackmar A. Diagnosis and treatment planning for unerupted premolars. *Pediatr Dent* 1994; 16(2):89–95.
- Rubin DM, Vedrenne D, Portnof JE. Orthodontically guided eruption of mandibular second premolar following enucleation of an inflammatory cyst: case report. *J Clin Pediatr Dent* 2002; 27(1):19–23.
- Takagi S, Koyama S. Guided eruption of an impacted second premolar associated with a dentigerous cyst in the maxillary sinus of a 6-year-old child. *J Oral Maxillofac Surg* 1998; 56(2):237–9.
- Hitchin AD. The unerupted mandibular premolar. *Br Dent J* 1966; 120(3):117–26.
- Yawaka Y, Kaga M, Osanai M, Fukui A, Oguchi H. Delayed eruption of premolars with periodontitis of primary predecessors and a cystic lesion: a case report. *Int J Paediatr Dent* 2002; 12(1):53–60.
- McDonald RE, Avery DR. Eruption of the teeth: local, systemic and congenital factors that influence the process. In: Dentistry for the child and adolescent. 6th ed. Mosby; 1994. p. 186–213.
- Frank CA. Treatment options for impacted teeth. *J Am Dent Assoc* 2000; 131(5):623–32.
- Kokich VG, Mathews DP. Surgical and orthodontic management of impacted teeth. *Dent Clin North Am* 1993; 37(2):181–204.
- Proffit WR, Fields HW. Contemporary orthodontics. 3rd ed. Mosby; 2000. p. 435, 538–541.
- Collett AR. Conservative management of lower second premolar impaction. *Aust Dent J* 2000; 45(4):279–81.
- Murray P, Brown NL. The conservative approach to managing unerupted lower premolars — two case reports. *Int J Paediatr Dent* 2003; 13(3):198–203.
- Azaz B, Steiman Z, Koyoumdjisky-Kaye E, Lewin-Epstein J. The sequelae of surgical exposure of unerupted teeth. *J Oral Surg* 1980; 38(2):121–7.
- Howard RD. Impacted tooth position: Unexpected improvements. *Brit J Orthod* 1978; 5(2):87–92.
- Orton JS, McDonald F. The eruptive potential of teeth: a case report of a wandering lower second premolar. *Eur J Orthod* 1986; 8(4):242–6.
- Lazarus AH. Nonsurgical management of ectopic teeth. *J Am Dent Assoc* 1989; 119(7):133–5.